

Functional Assessment of Carotid-Cerebral Artery from Noninvasive Imaging

Hyun-Seung Kang

Professor, Department of Neurosurgery, Seoul National University Hospital,
Seoul National University College of Medicine

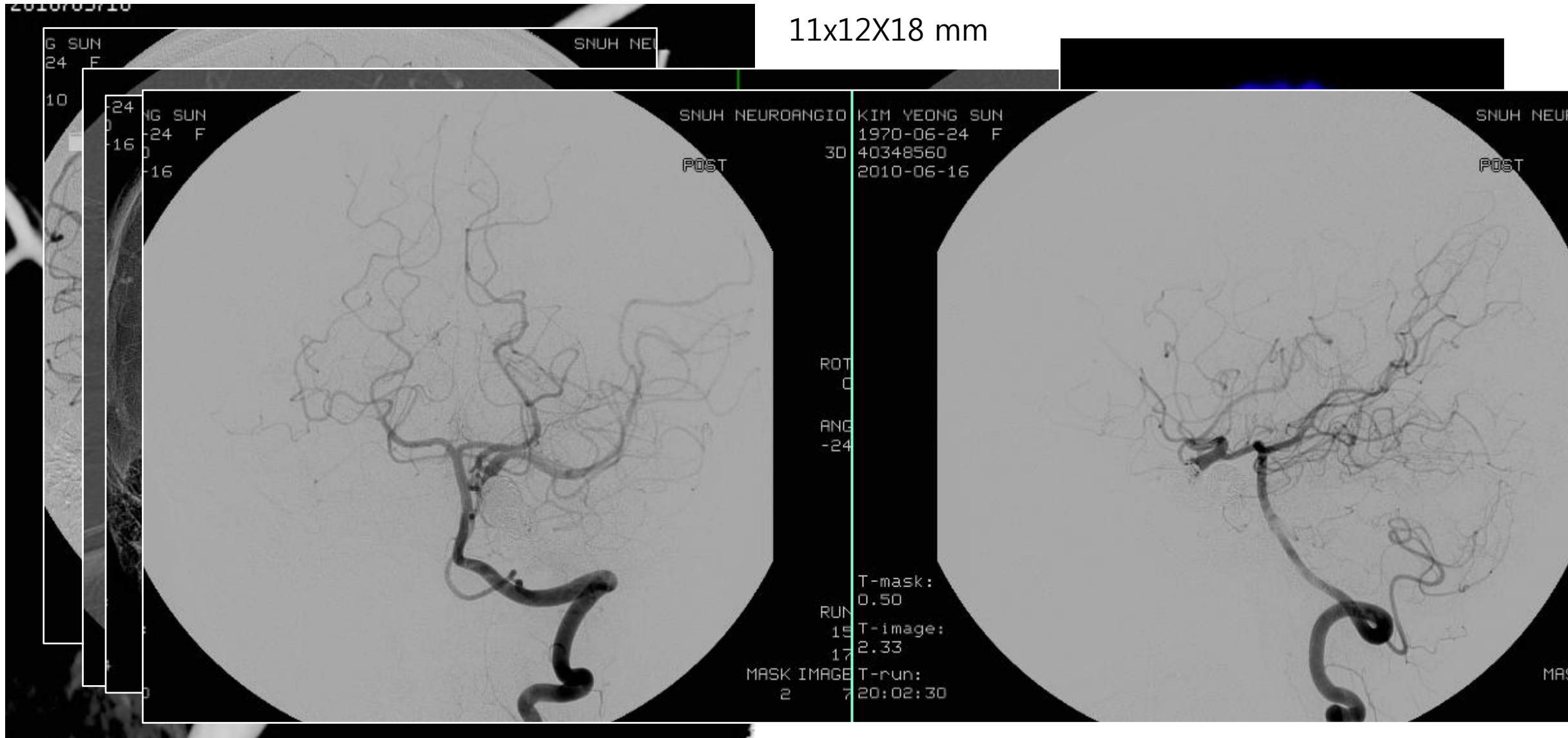
Agenda

- Cerebrovascular imaging: Tools
- Cerebral hyperperfusion
- Arterial spin labeling MR perfusion imaging
- Near-infrared spectroscopy

Cerebrovascular Imaging: Tools

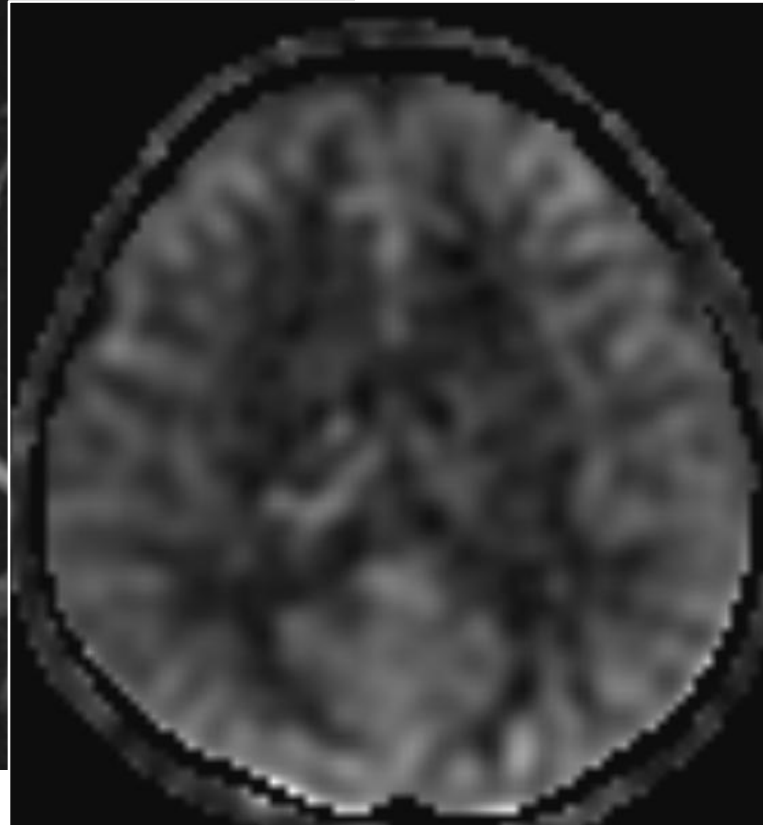
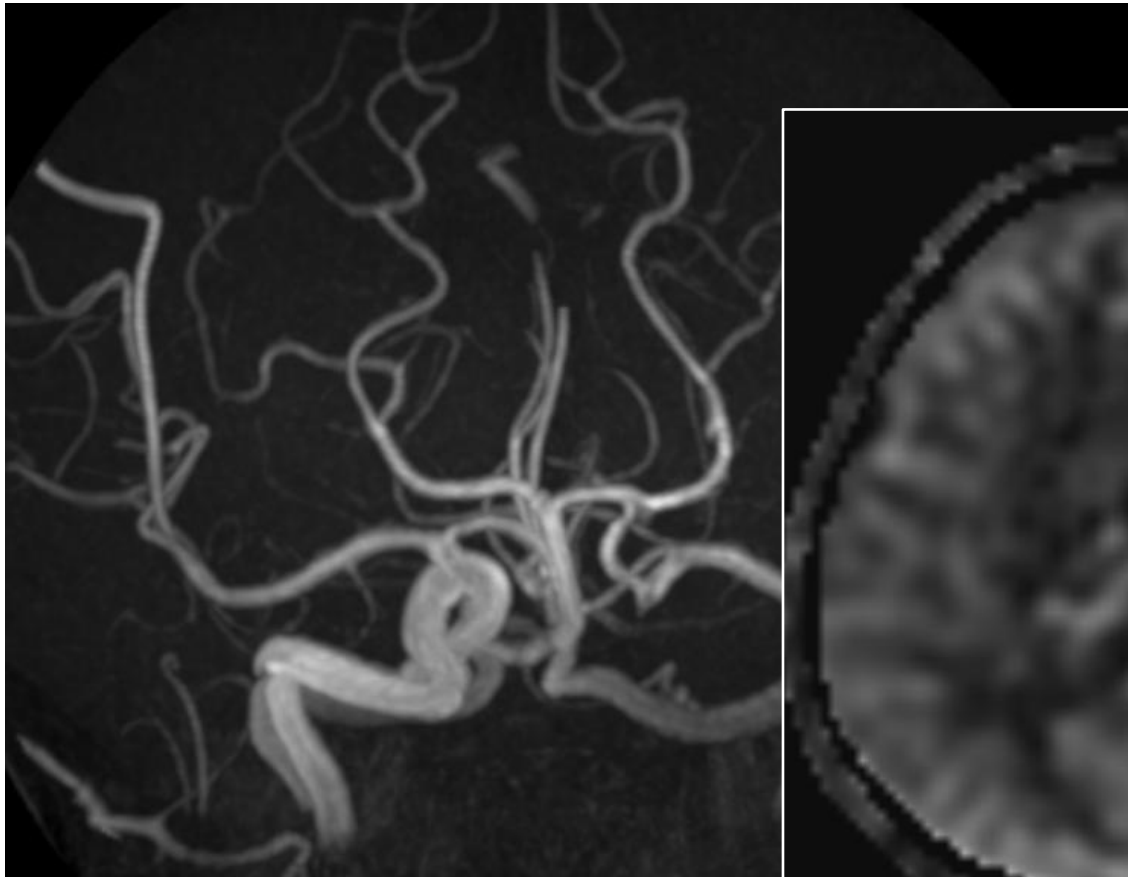
- **CT-based**
 - CT angiography
 - CT perfusion
- Xenon-enhanced CT
 - Inert, inhalable; cross BBB; short half-life (40 seconds)
- **MR-based**
 - MR angiography
 - Time-of-flight [TOF], Phase-contrast (*quantitative* MRA; NOVA), Contrast-enhanced
 - MR perfusion
- **SPECT**
 - Tc99m-HMPAO (hexamethylpropyleneamine oxime); *problems in quantification*
 - Balloon occlusion test

KYS F/40 headache, dizziness; very large carotid An.

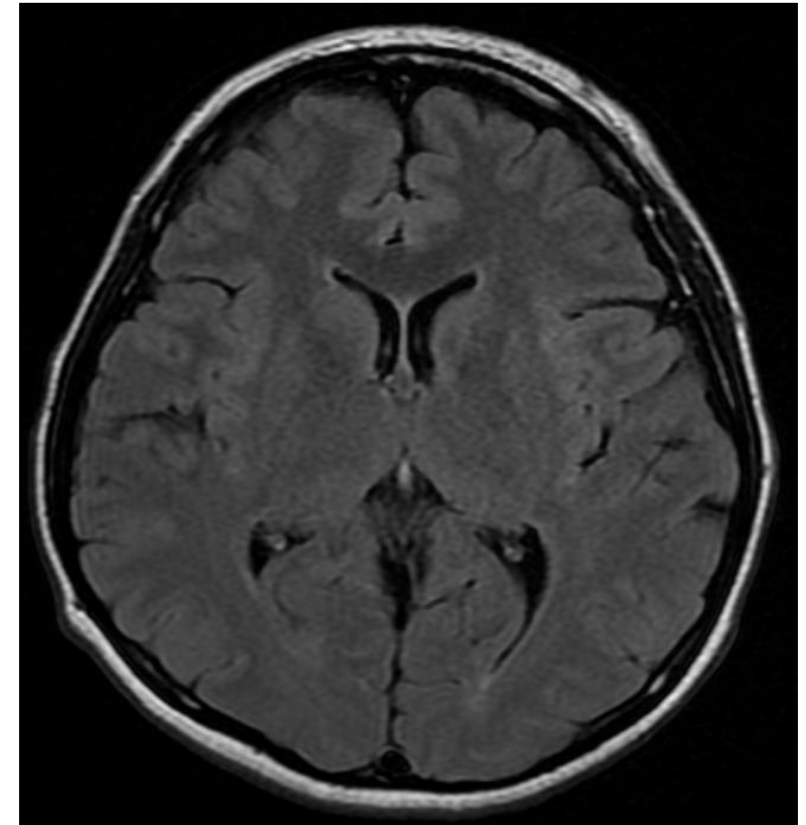


KYS F/40 headache, dizziness; very large carotid An.

Post treatment 4 yrs



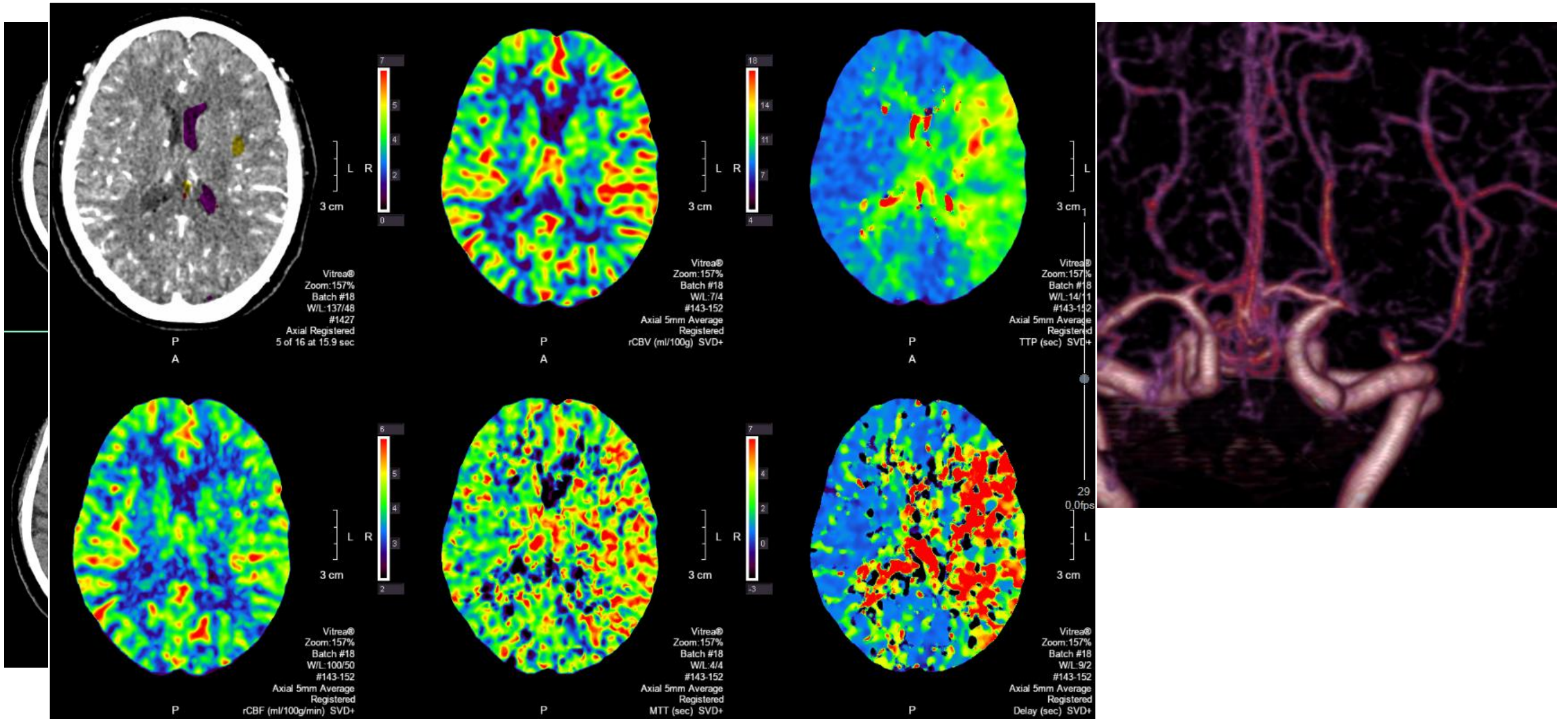
ASL



Acute stroke imaging: CT-based

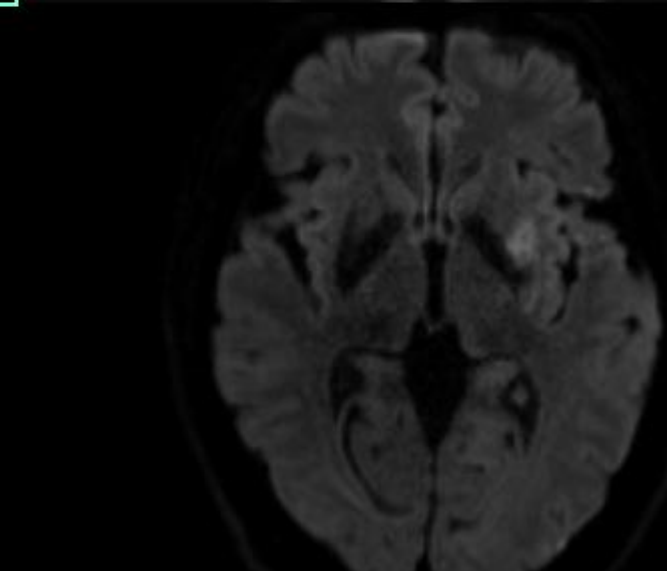
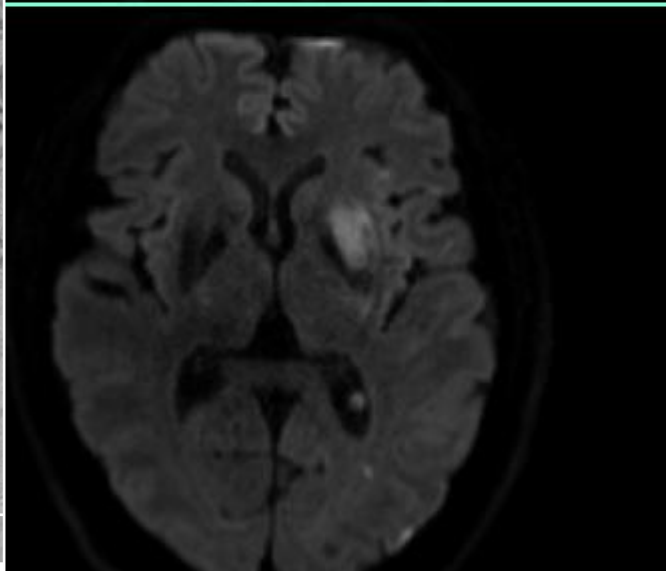
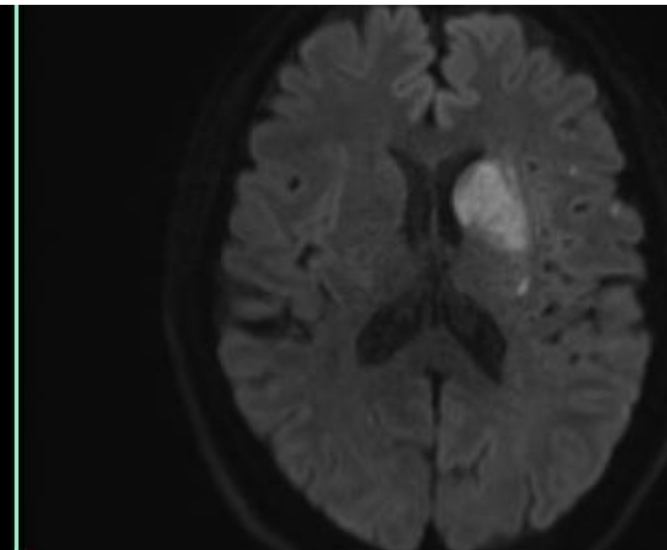
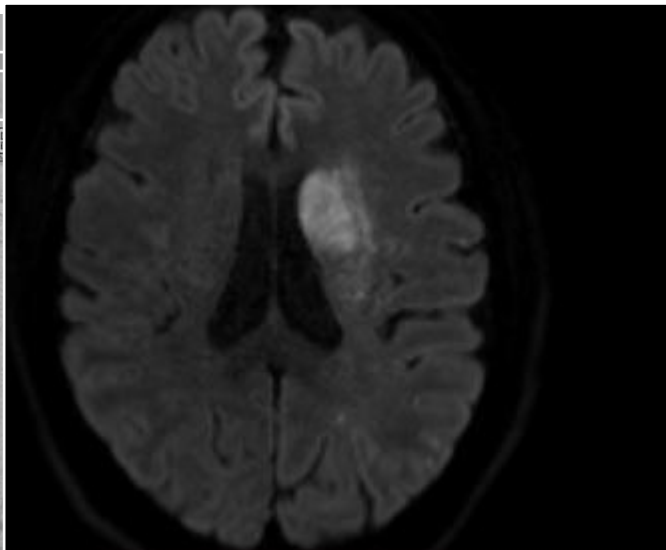
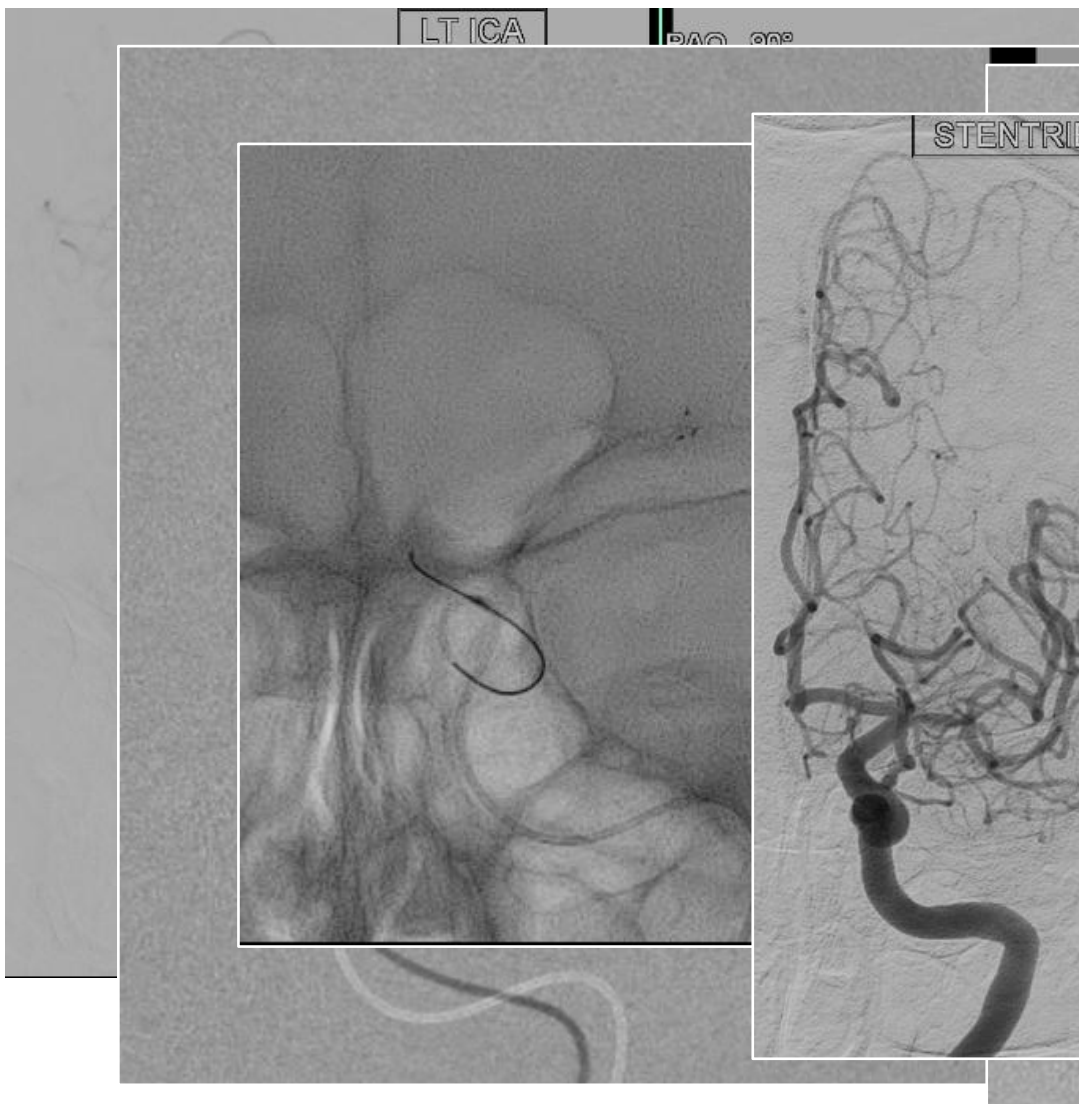Aquilion ONE 320 [9:50 ~ 10:07]

F/72 HT; Rt side weakness (1d), aphasia (30min); iNIHSS 8

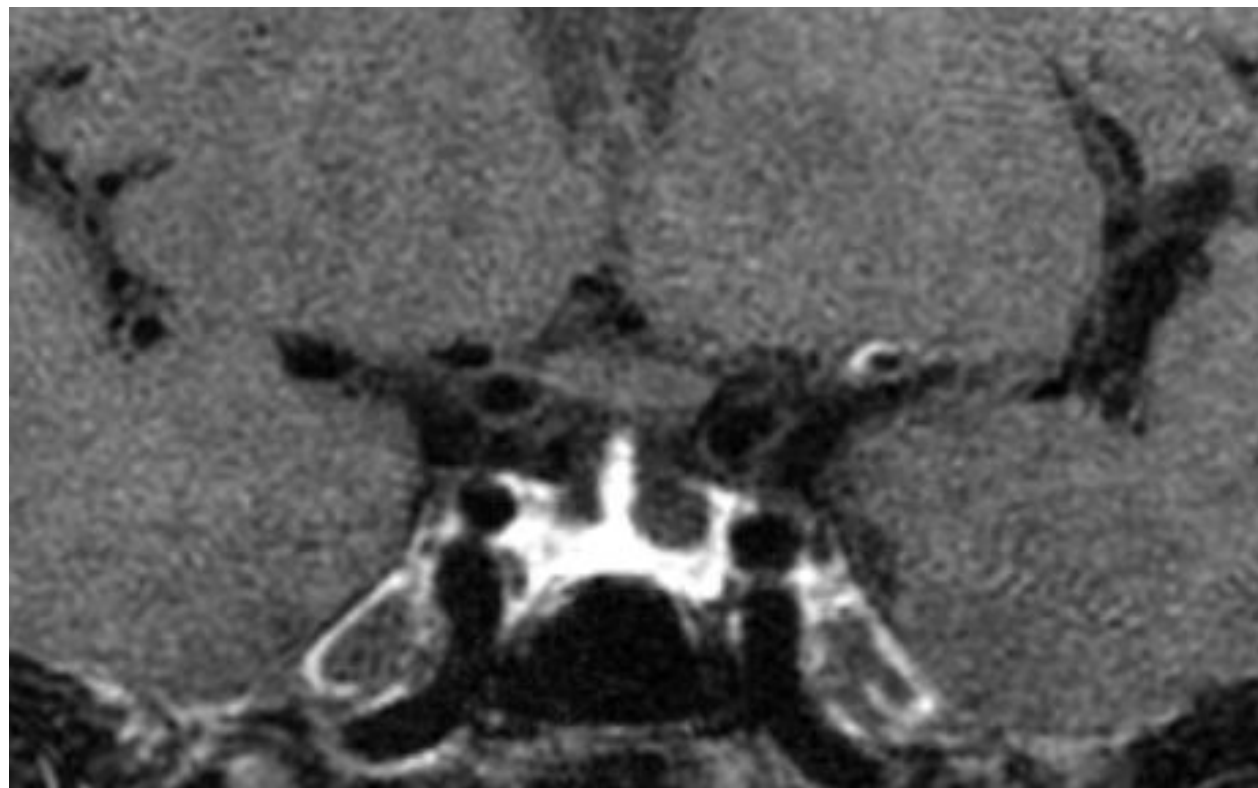
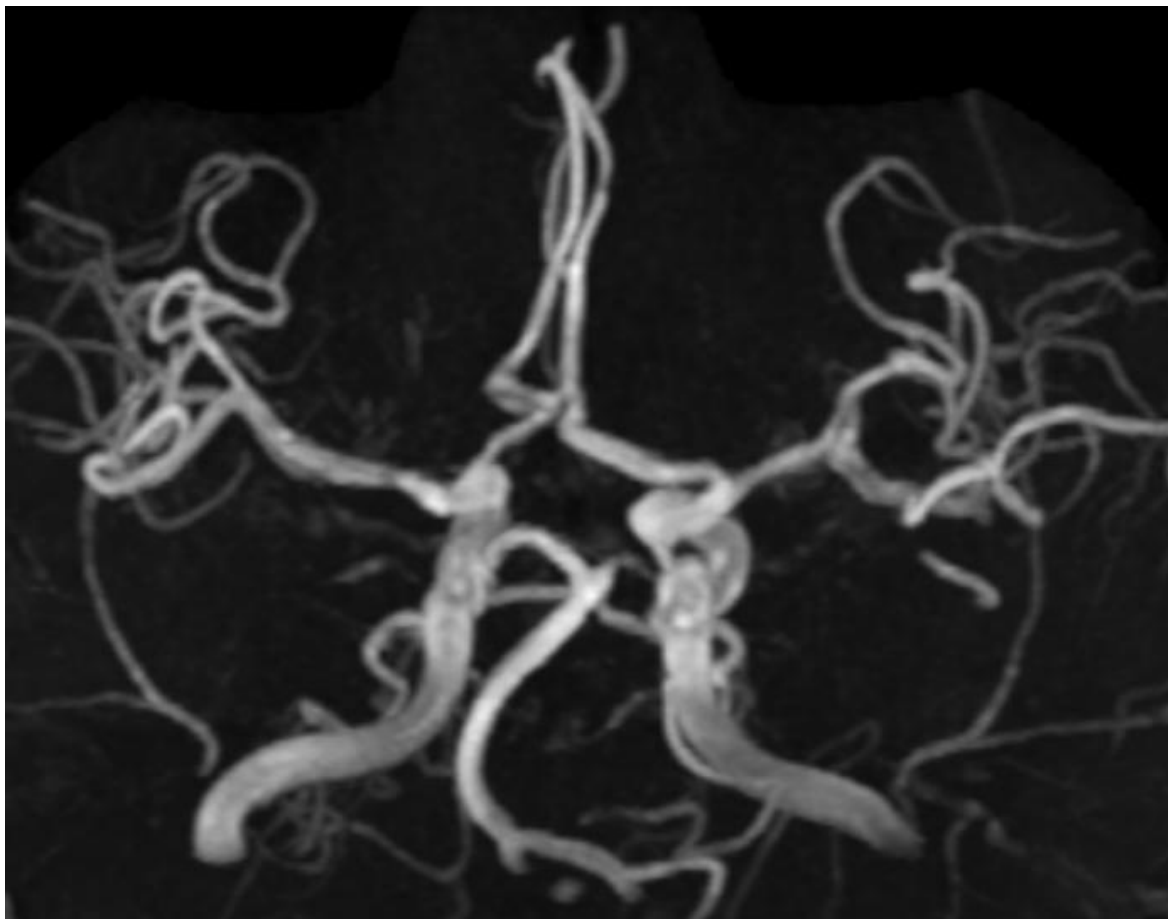


Acute stroke imaging: CT-based

F/72 HT; Rt side weakness (1d), aphasia (30min); iNIHSSS 8



F/72 HT; Rt side weakness (1d), aphasia (30min); iNIHSSS 8

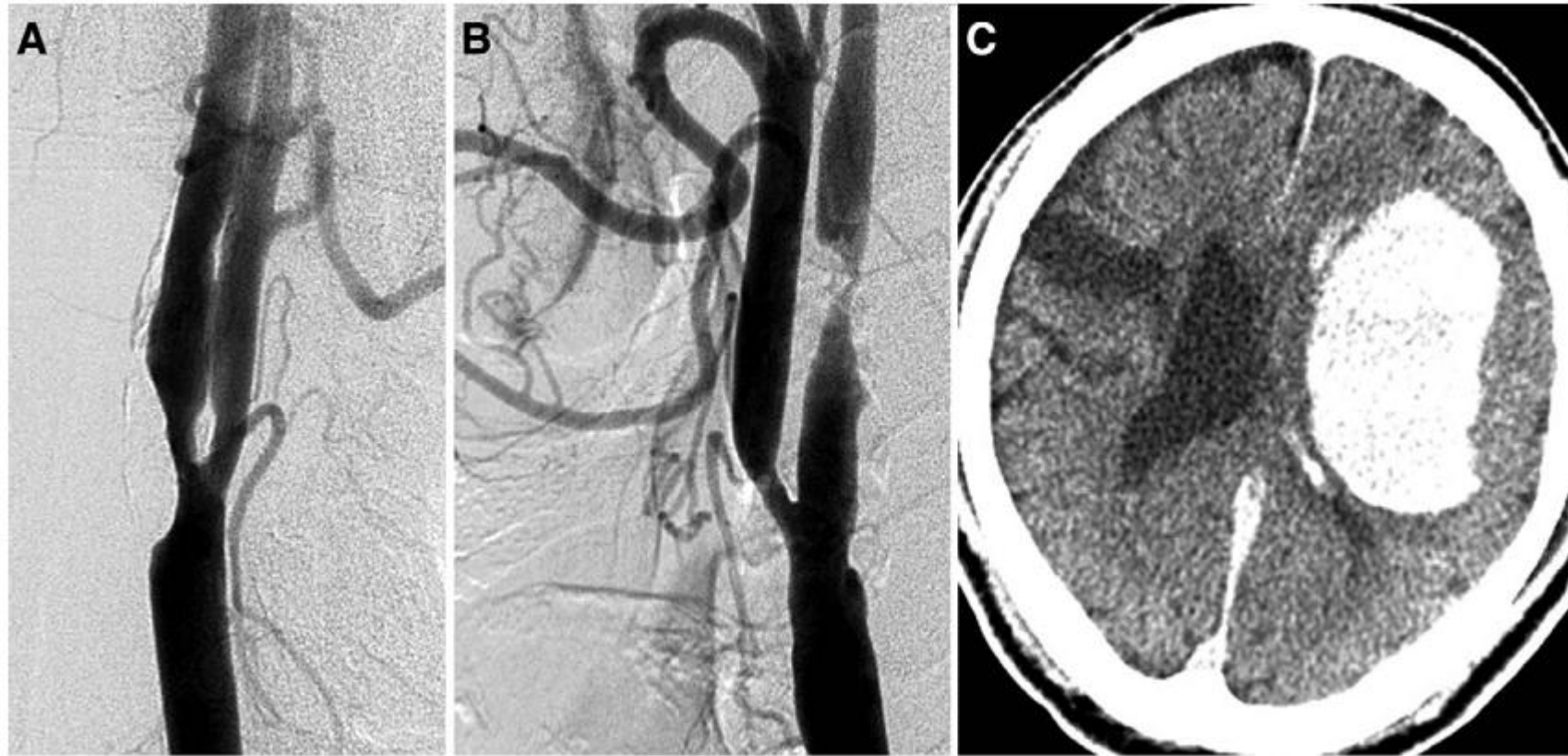


Cerebral hyperperfusion

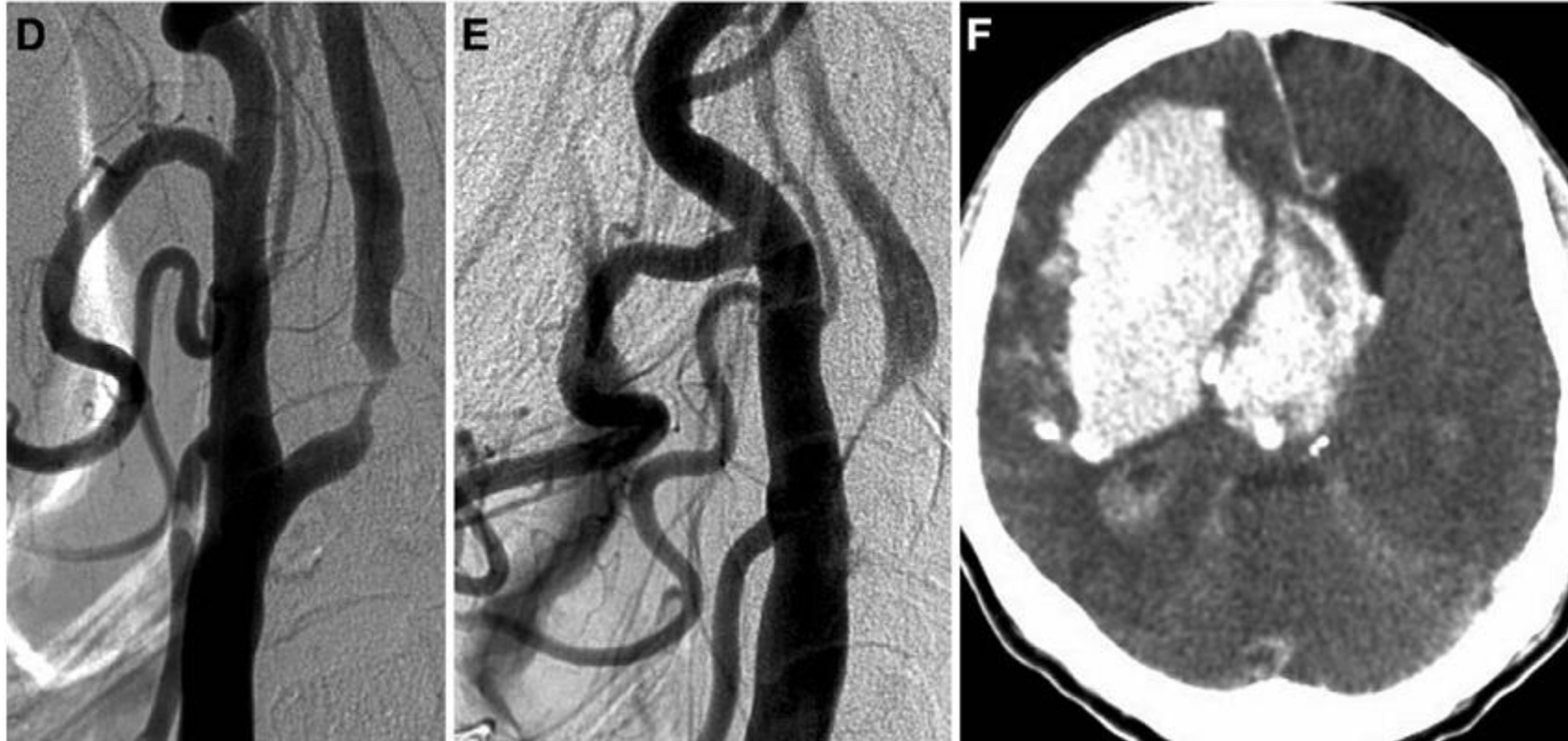
Cerebral hyperperfusion & ICH after revascularization

- Symptomatic cerebral hyperperfusion on SPECT after indirect revascularization surgery for Moyamoya disease. Clin Nucl Med. 2013
- Intracranial hemorrhage after carotid angioplasty: a pooled analysis. J Endovasc Ther. 2007

M/80 *Recurrent right hemiparesis.* Stent-assisted angioplasty at the left carotid (B), and then right (A); Immediately after the procedure, the patient's condition deteriorated (C).



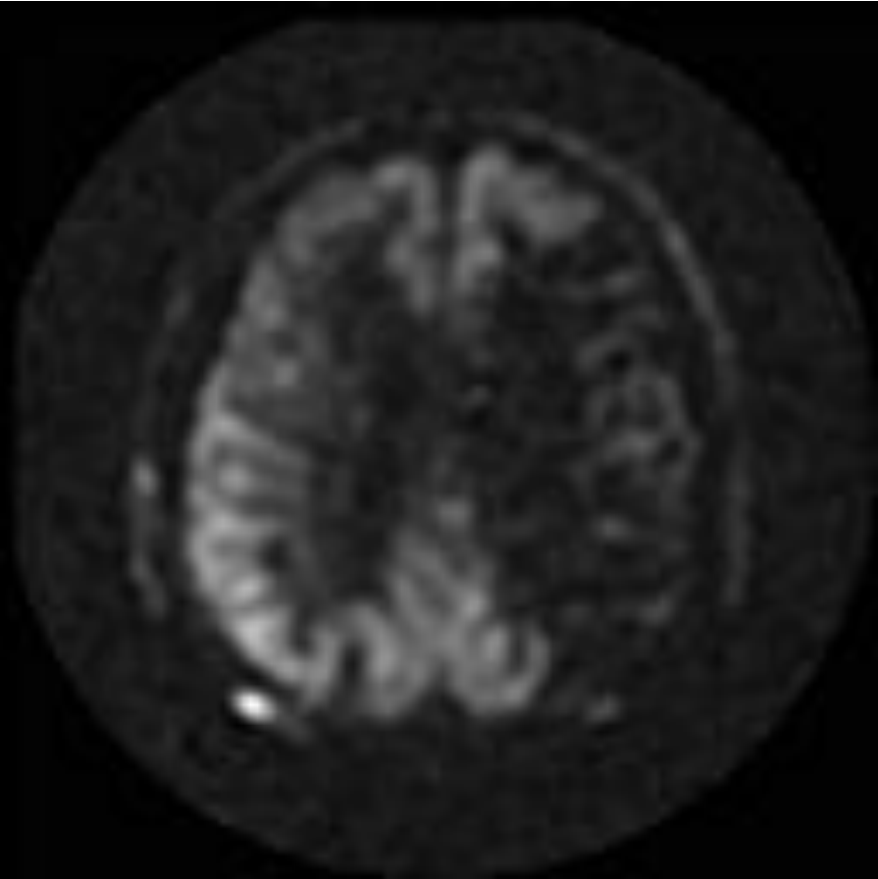
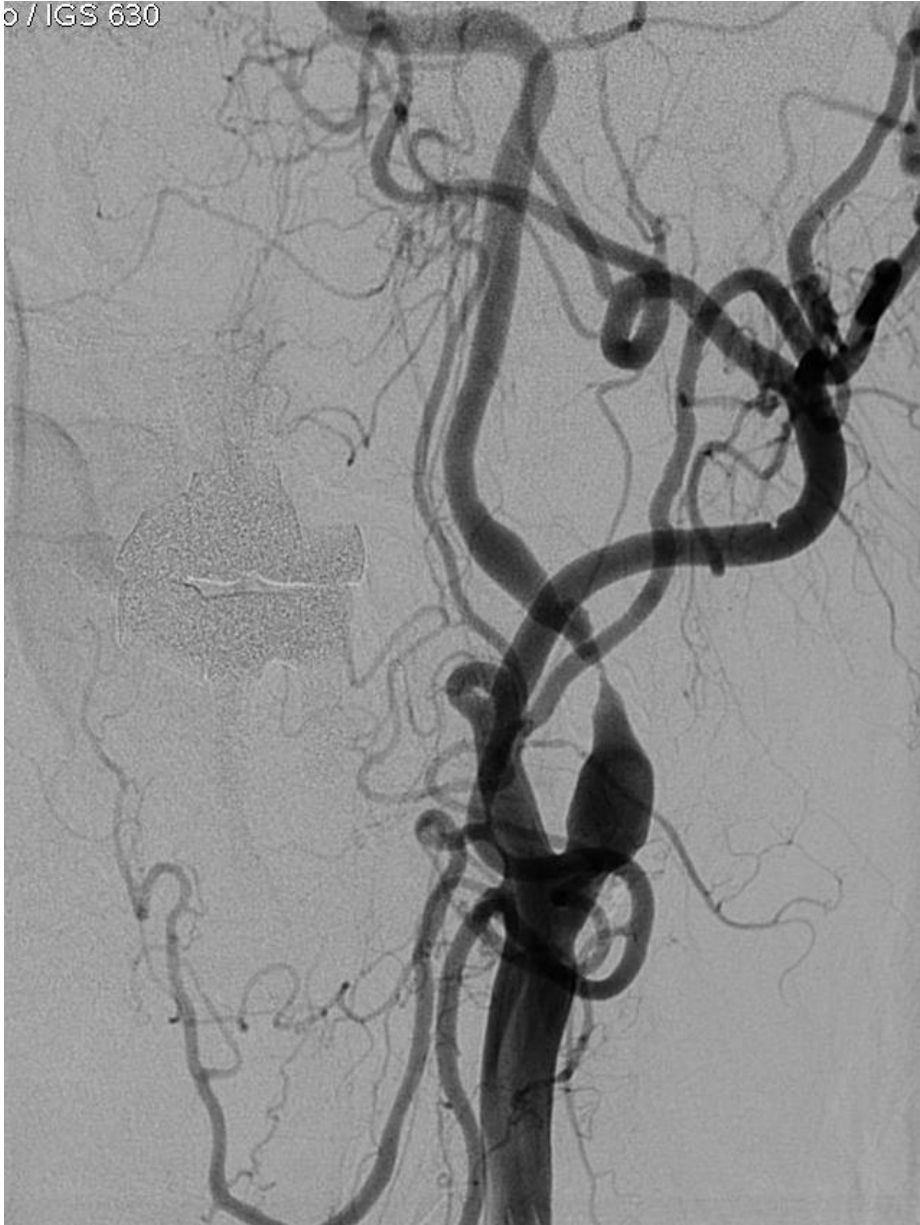M/69 *Left-sided TIA*. Stent-assisted angioplasty at the right carotid (D), and then left (E); immediately after the procedure, the patient became comatose (F).



CAS-associated ICH

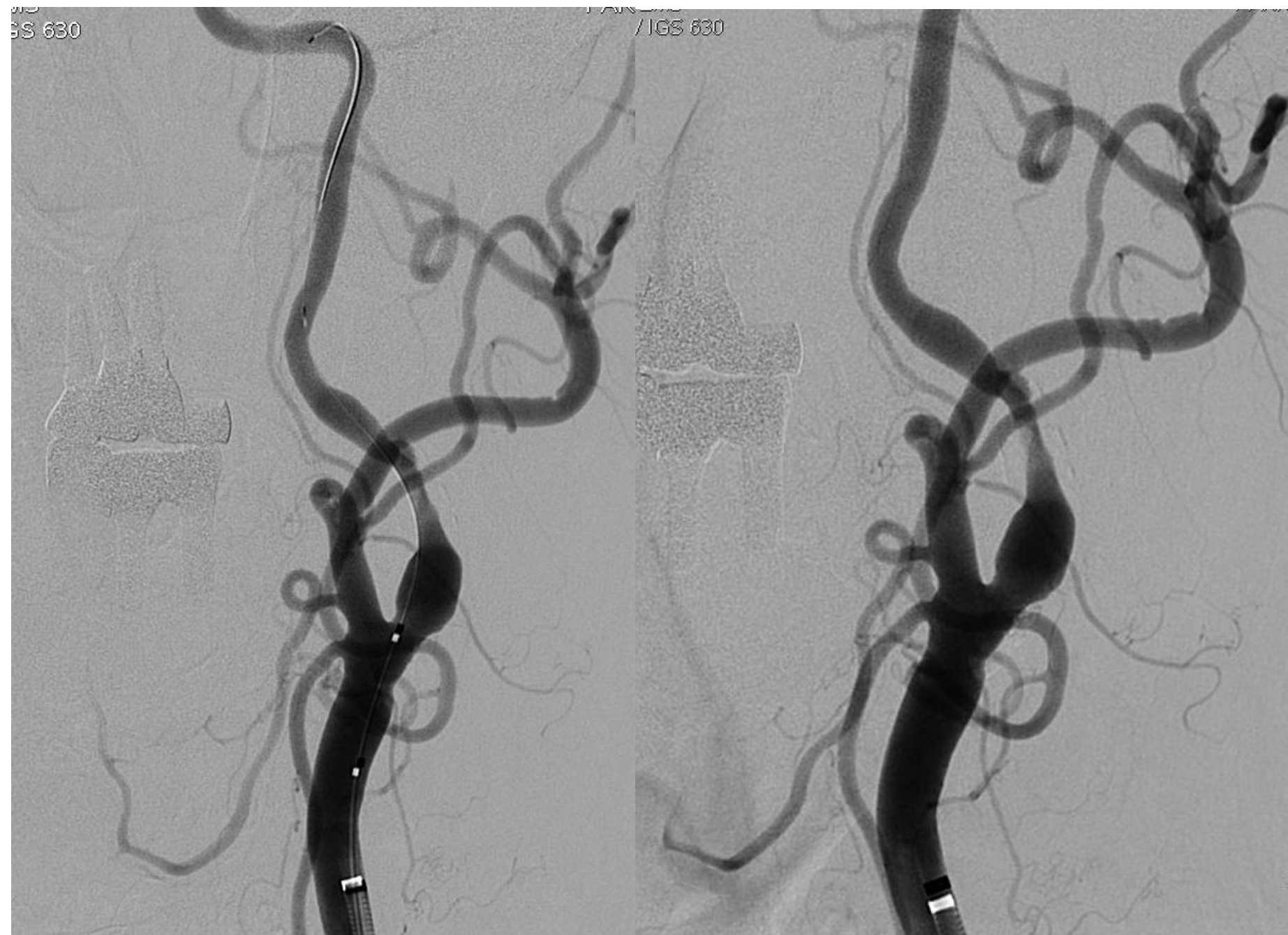- The incidence of CAS-associated ICH was **0.63%** (95% CI 0.38% to 0.97%) in studies consisting of >100 cases, which was significantly lower ($p < 0.0001$) than that of case series consisting of <100 cases (**2.69%**, 95% CI 1.75% to 3.94%).
- Distinctive features included
 - ***symptomatic*** lesions,
 - ***severe stenosis*** (>90%),
 - maximal stenosis in the internal carotid artery (ICA) ***distal to the bifurcation***, and
 - ***preexisting cerebral infarction***.

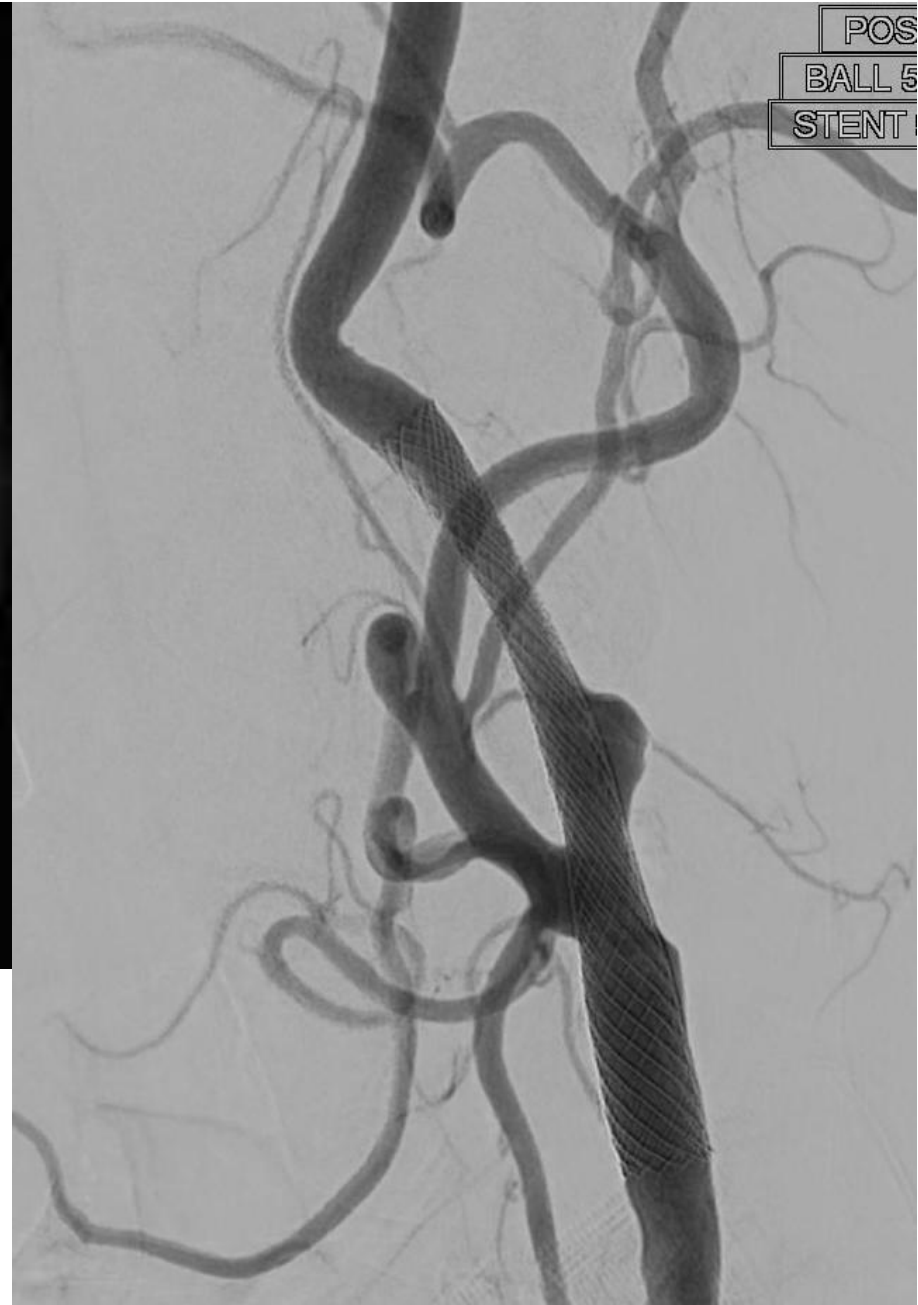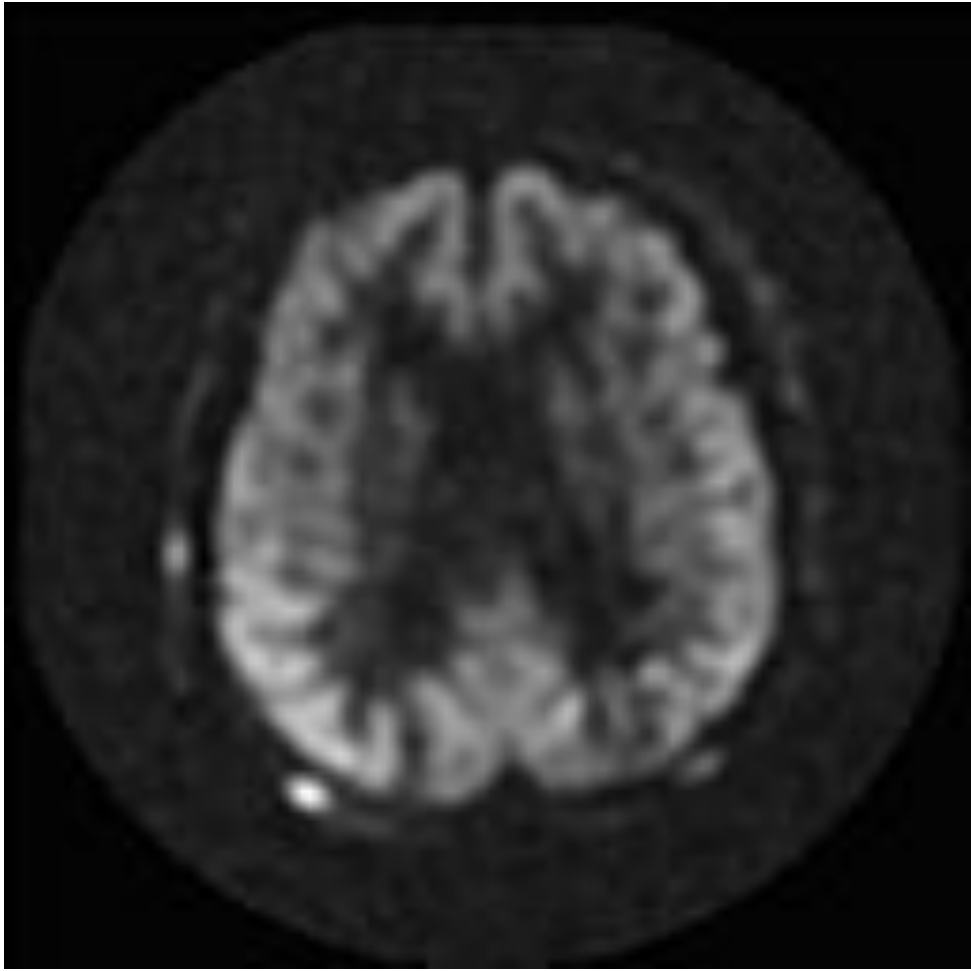
M/81 Lt side **symptomatic** stenosis



SS 630

/IGS 630



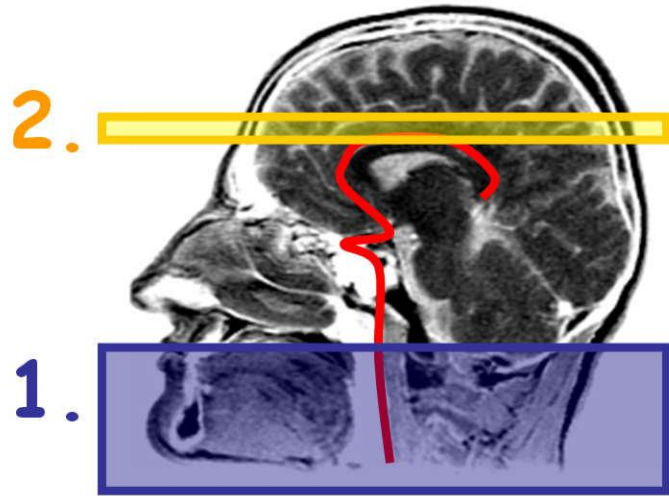


Arterial spin labeling MR perfusion imaging

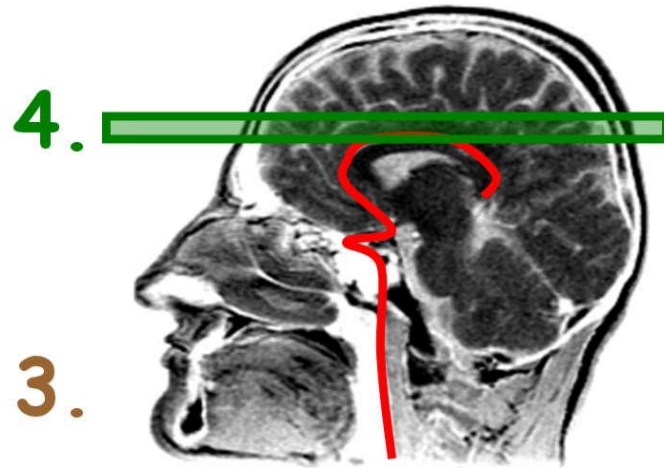
Arterial spin labeling MR perfusion imaging

- Endogenous tracers to assess cerebral blood flow
- Uses radiofrequency pulses for the noninvasive labeling of **water protons** in the blood
- **Completely noninvasive** (does not require gadolinium-based contrast nor radioactive material for injection)
- Provides information on **absolute CBF** (ml /100 g tissue /min) at the brain tissue level
- Repeatability: comparisons between pre- and postprocedural images performed with a brief interval

Principle of ASL



1. **Tag** inflowing arterial blood by magnetic inversion
2. Acquire the **tag image**



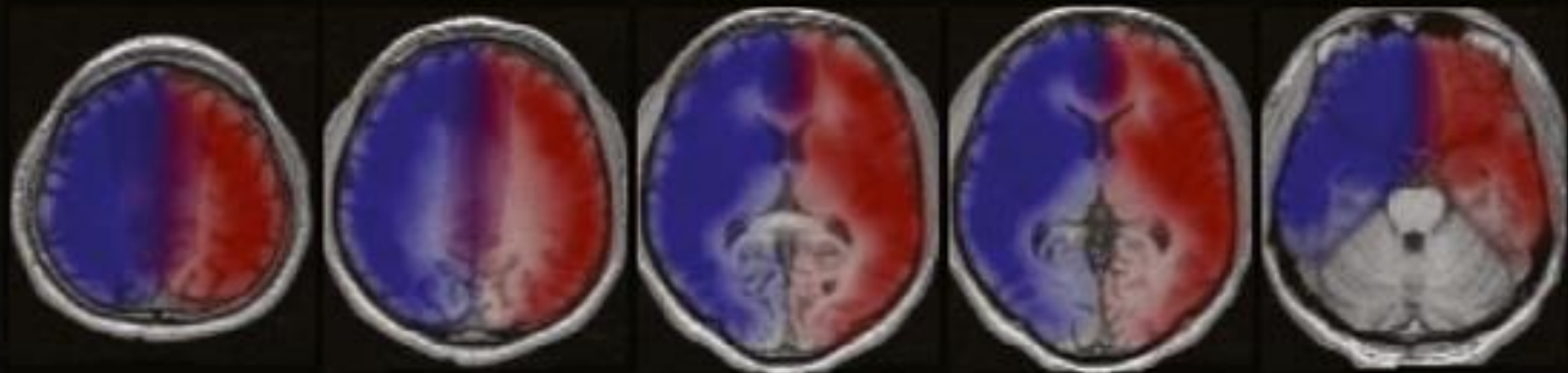
3. Repeat experiment without **tag**
4. Acquire the **control image**

$$\uparrow - \uparrow = \uparrow \propto \text{CBF}$$

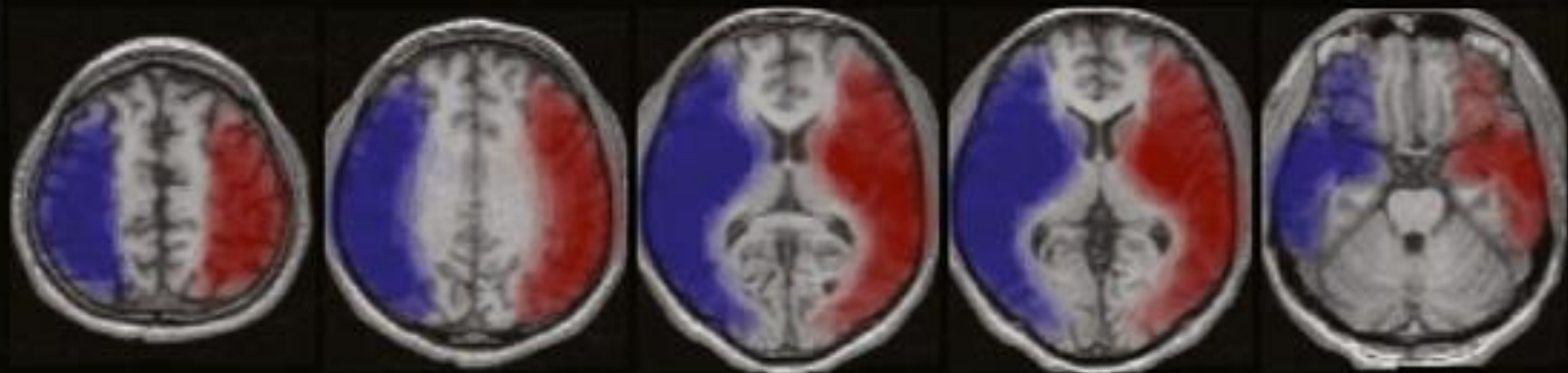Arterial spin labeling MR perfusion imaging

- Effect of ***carotid artery stenting*** on cerebral blood flow: evaluation of hemodynamic changes using *arterial spin labeling*. *Neuroradiology*. 2013
- Effect of delayed transit time on *arterial spin labeling*: correlation with dynamic susceptibility contrast perfusion magnetic resonance in ***moyamoya disease***. *Invest Radiol*. 2013
- Bright vessel appearance on *arterial spin labeling* MRI for localizing arterial occlusion in ***acute ischemic stroke***. *Stroke*. 2015
- Utility of *arterial spin labeling* perfusion magnetic resonance imaging in prediction of angiographic vascularity of ***meningiomas***. *J Neurosurg*. 2016

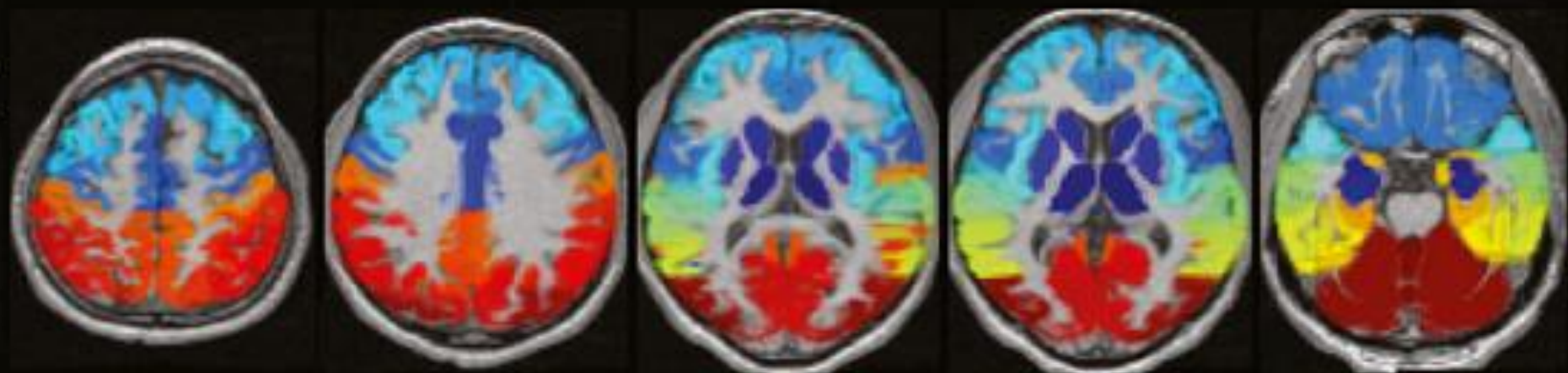
Vascular
territory -
based ROI
ICA

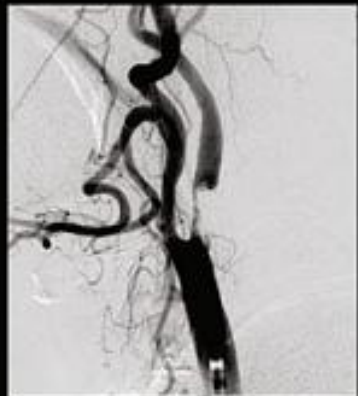

Vascular
territory -
based ROI
MCA

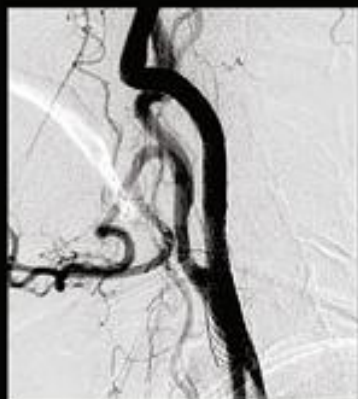

Anatomical
structure -
based ROI





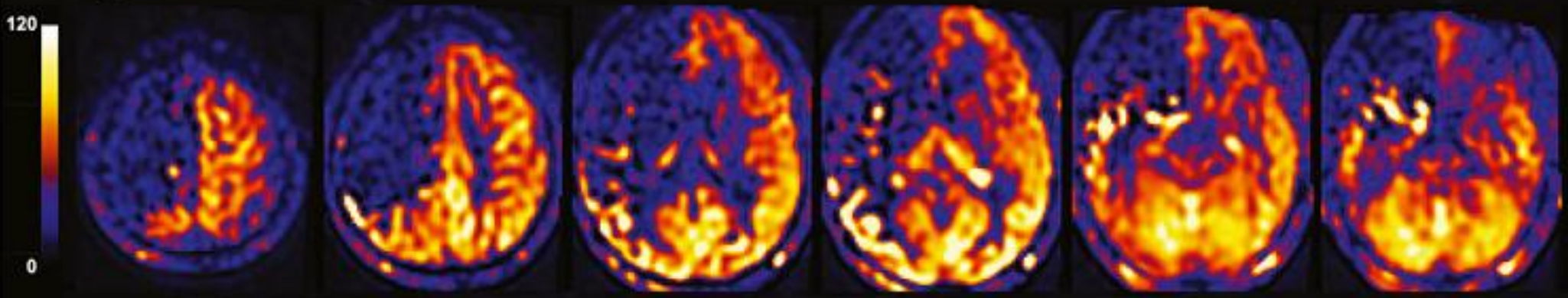
Preprocedural



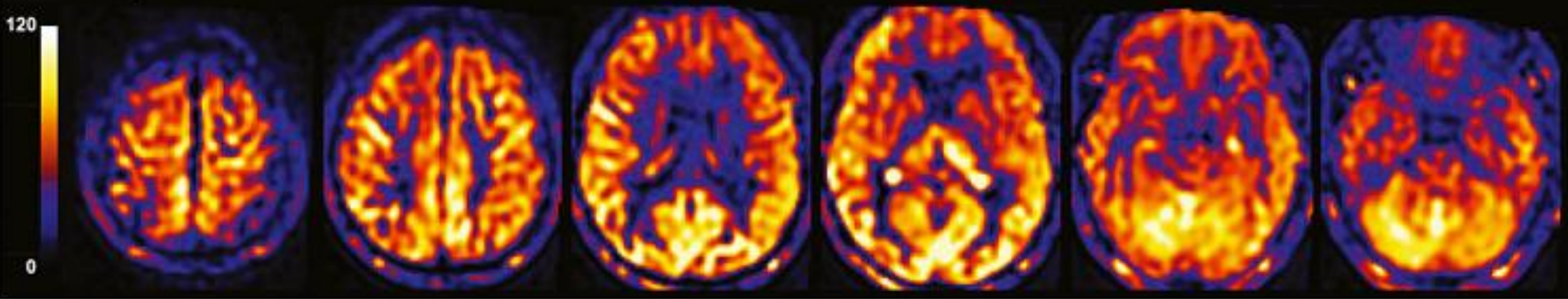
Postprocedural



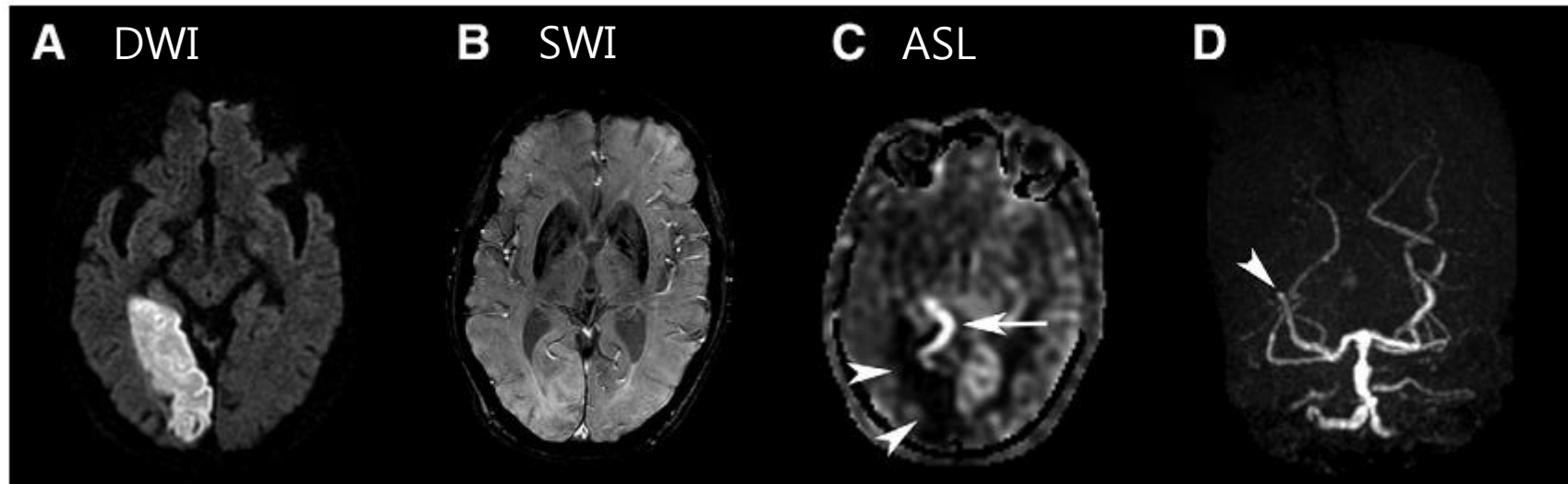
Preprocedural 28.9 mL/100g/min



Postprocedural 50.4 mL/100g/min



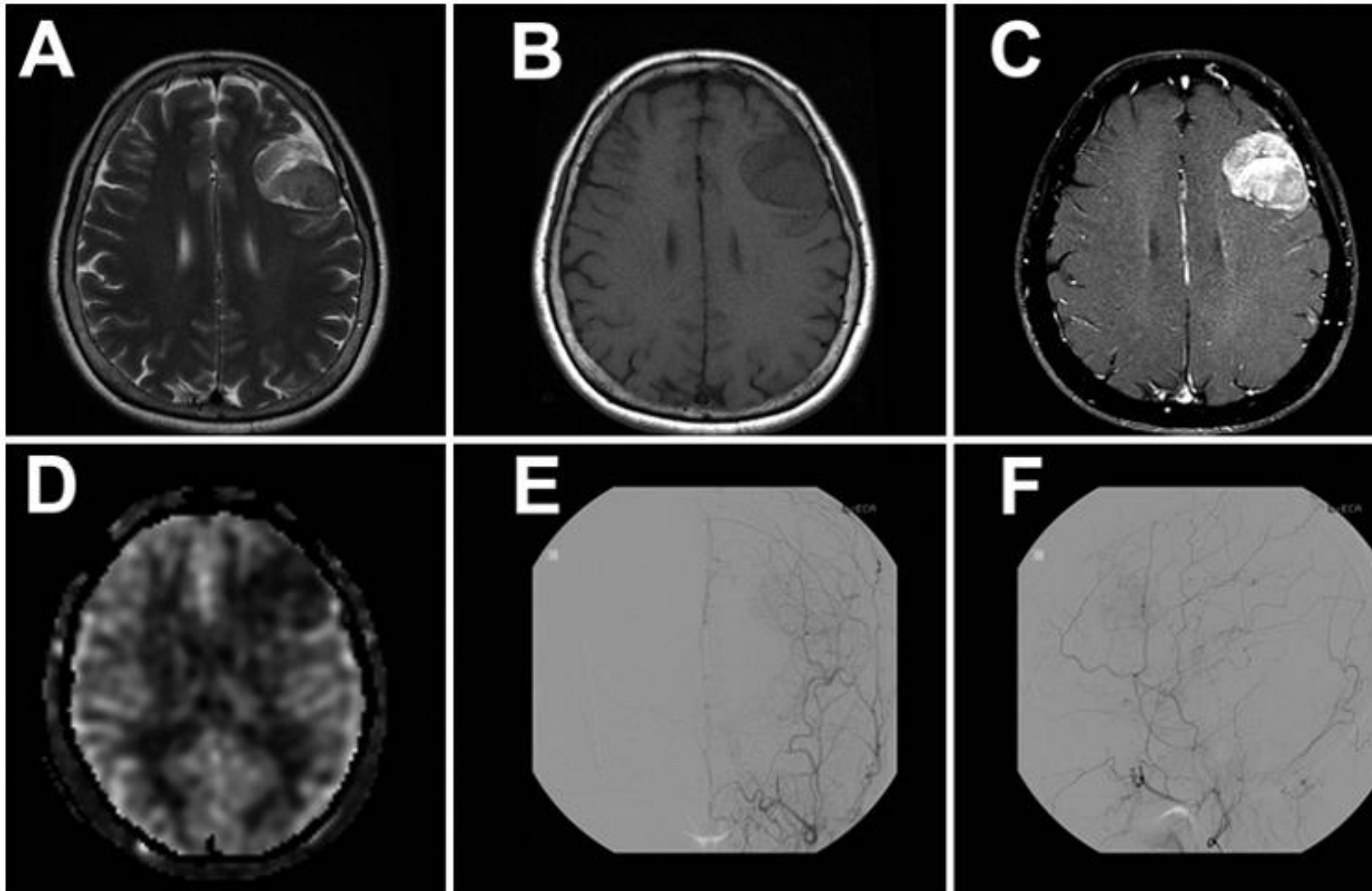
Bright vessel appearance in *acute ischemic stroke*



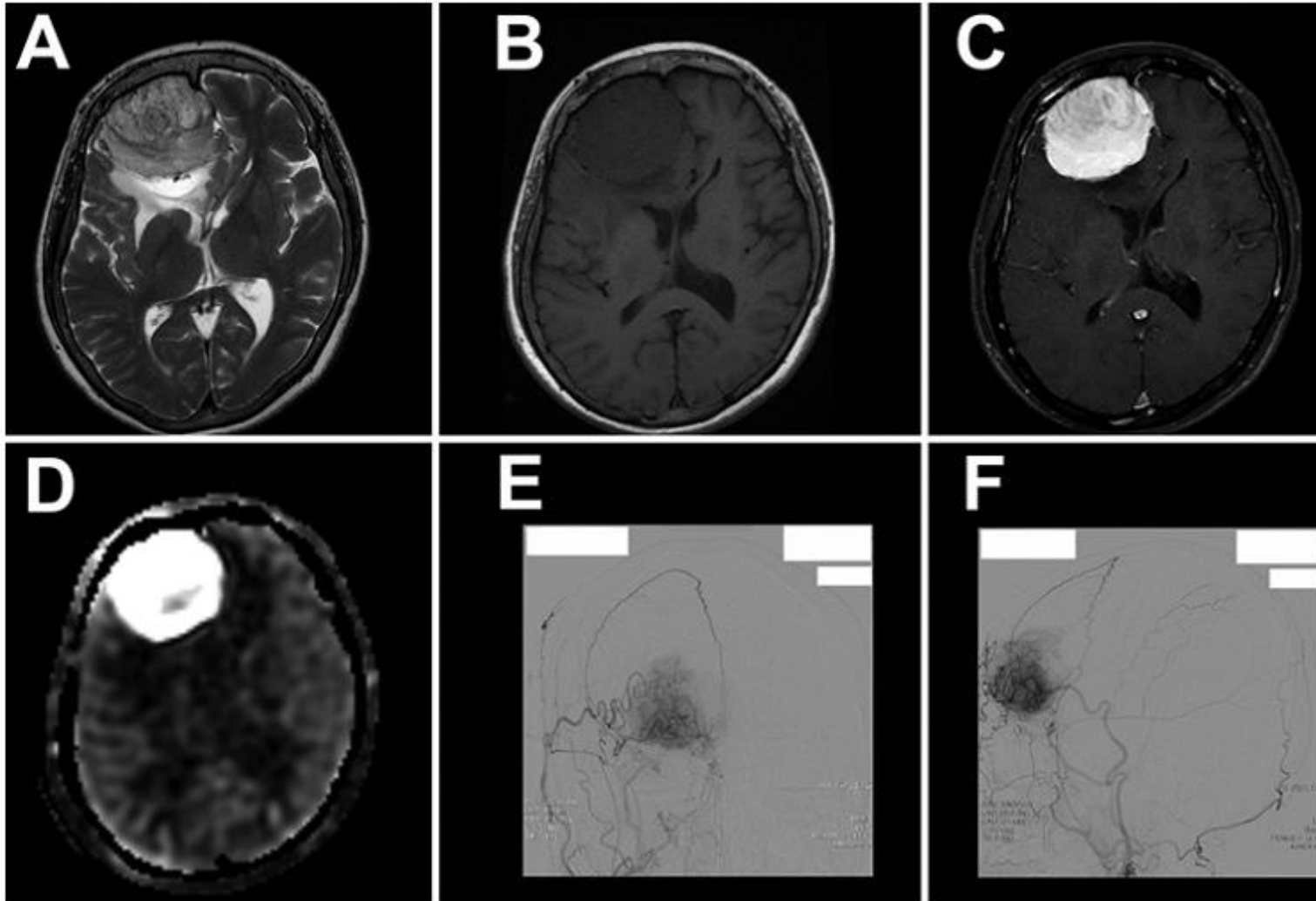
76/M sudden-onset left homonymous hemianopsia

- In the presence of delayed arterial transit, the late-arriving flow is delineated as a bright intravascular signal.
- An occluded arterial segment with sluggish blood flow in acute ischemic stroke show a bright intravascular signal because of arterial transit artifact; higher sensitivity for the detection of occlusion than the susceptibility vessel sign (94% [33 of 35] versus 66% [23 of 35], respectively; $P=0.002$).

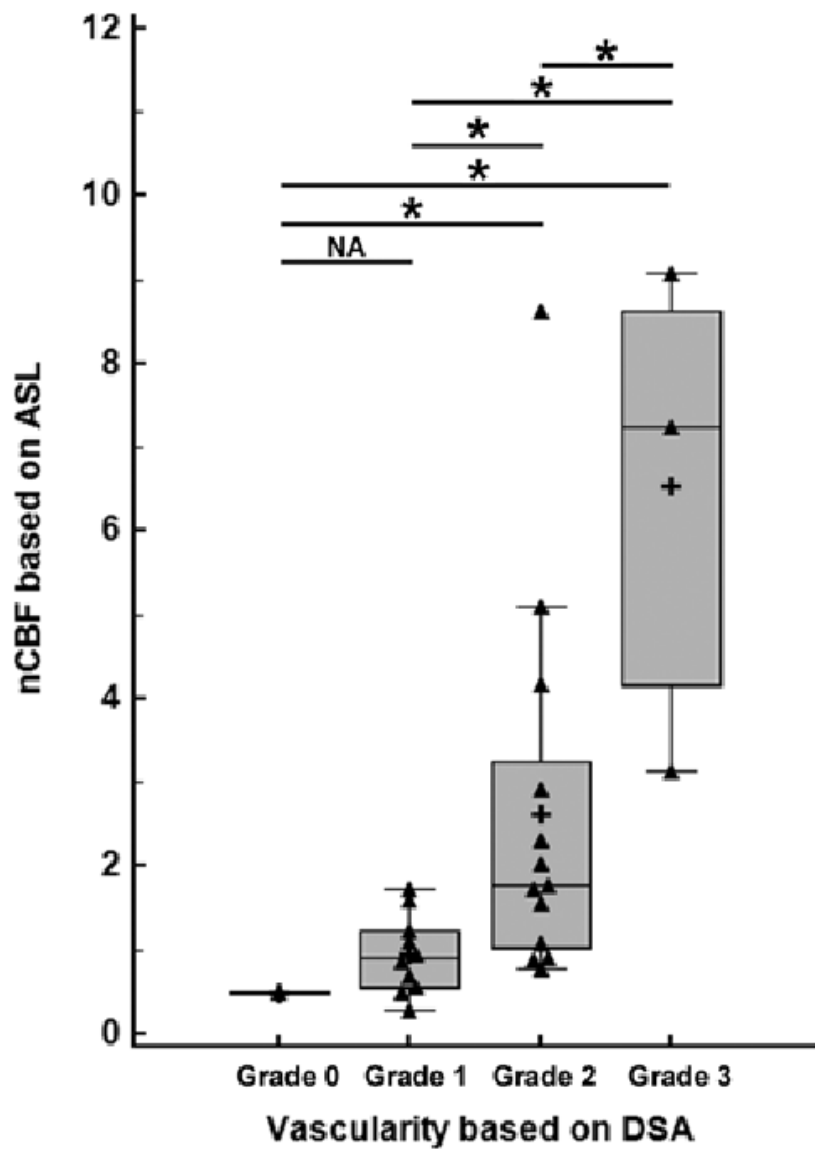
ASL & angiographic vascularity of meningiomas



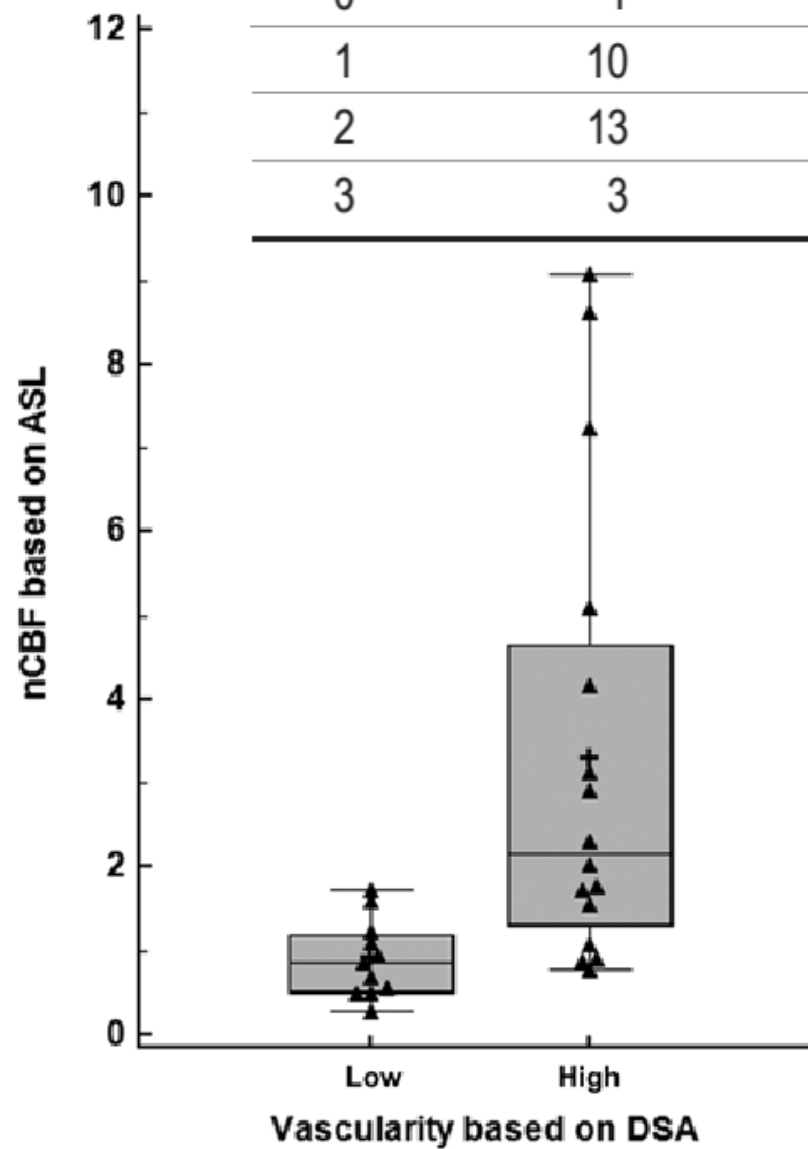
- Angiographic vascularity, Grade 1
- Normalized CBF, 0.286



- Angiographic vascularity, Grade 3
- Normalized CBF, 9.089



Grade	No. of Patients	nCBF*
0	1	0.493
1	10	0.951 ± 0.471 (0.911, 0.595–1.193)
2	13	2.604 ± 2.227 (1.765, 1.079–2.927)
3	3	6.494 ± 3.045 (7.250, 5.196–8.170)



Near-infrared spectroscopy

Near-infrared spectroscopy (NIRS)

- **Measurement of capillary–venous oxyhemoglobin saturation in tissues [rSO₂]**
 - To estimate mixed venous saturation
 - To characterize regional and global circulatory function
 - 700–900 nm; differential absorption of at least two light wavelengths of light; a dual detector system
 - Usually 830 and 780 nm; 780, 805 and 830 nm; 775, 810, and 850 nm; 695 and 830 nm
- **Modified Beer-Lambert law**
 - measurement of concentration of a substance according to the absorption and scatter of light

Multisite cerebral and somatic NIRS monitoring

- Mean baseline cerebral rSO₂, **70%** in healthy adults
- Arterial saturation–cerebral rSO₂ difference, **30%**
- Comparison of oxygen extraction across the cerebral bed compared with the somatic bed
- renal, splanchnic or muscular rSO₂
- Wearable NIRS

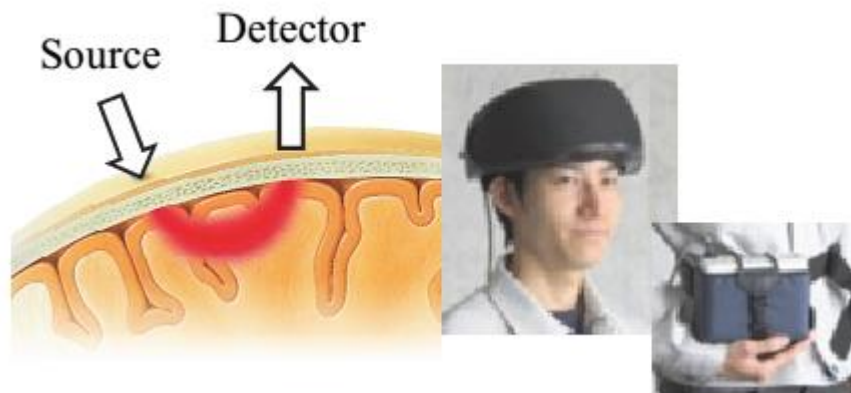


TABLE 2. NIRS probe placement

NIRS	Location of probe
Renal	Latissimus dorsi, posterior flank, T10-L2 vertebrae, paramedian position
Splanchnic	Lower abdomen, external oblique muscle
Cerebral	Frontal bone, supraorbital paramedian position
Muscular	Pectoralis (chest), over brachioradialis (forearm), biceps (upper arm), thenar (palm) or gastrocnemius (calf) muscle

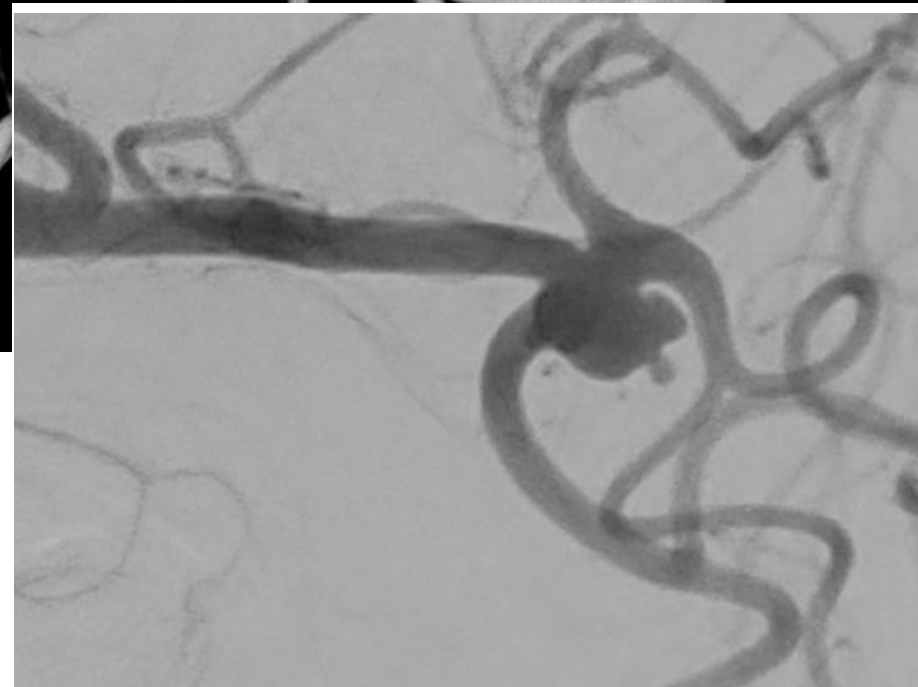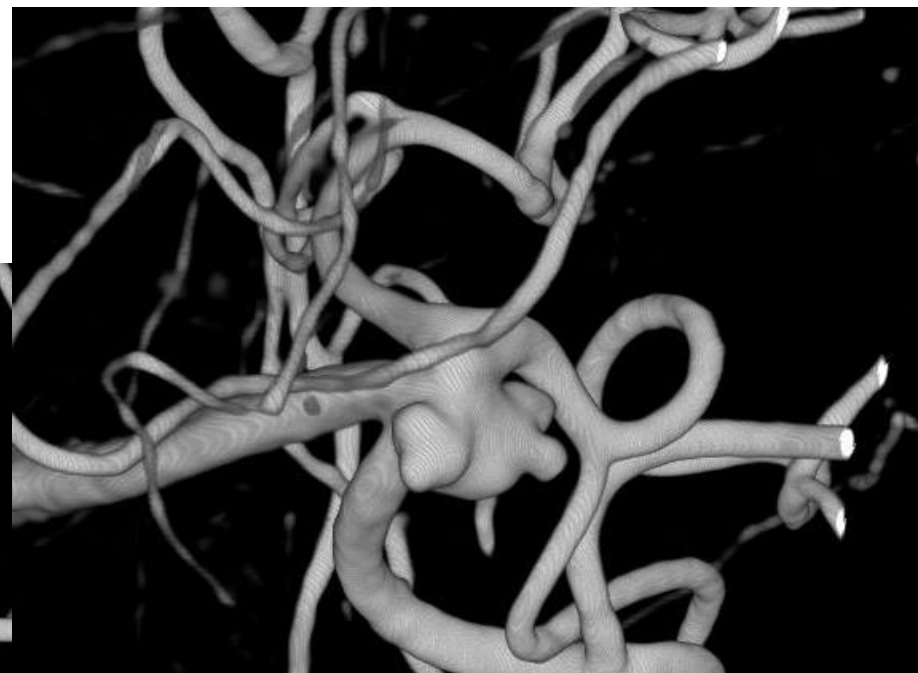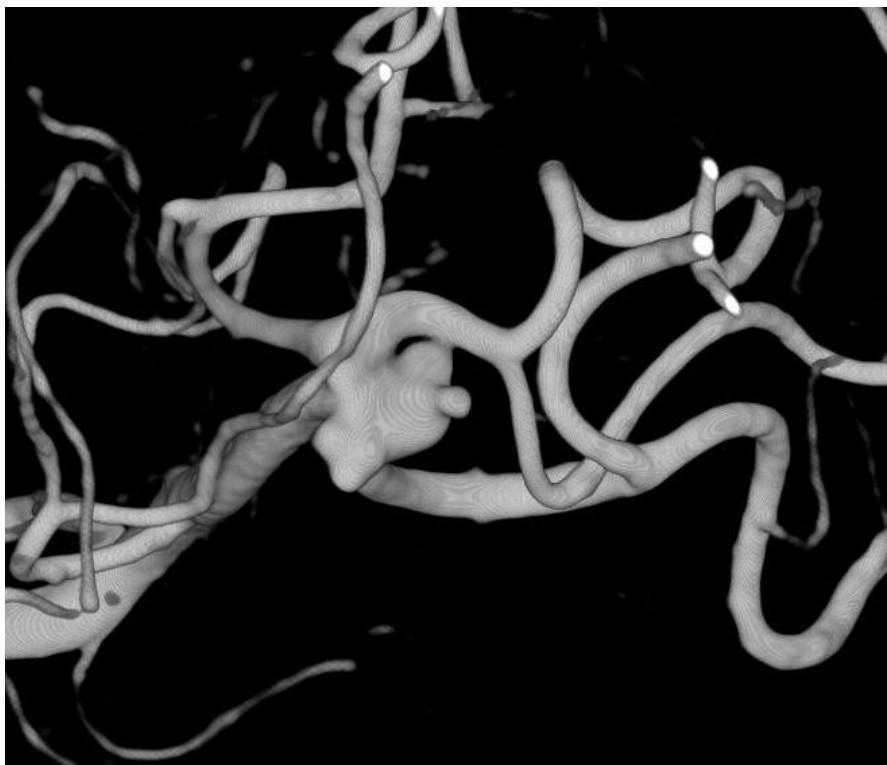
Thresholds for cerebral injury in adults

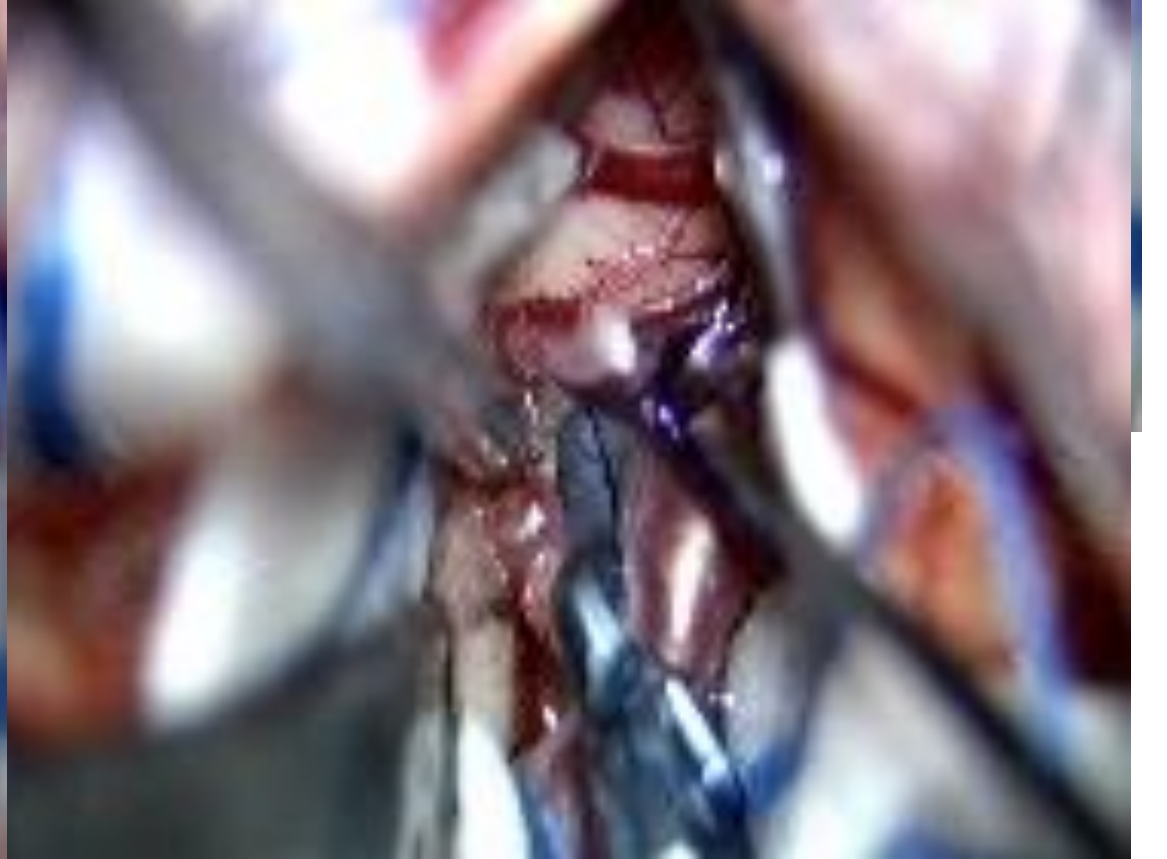
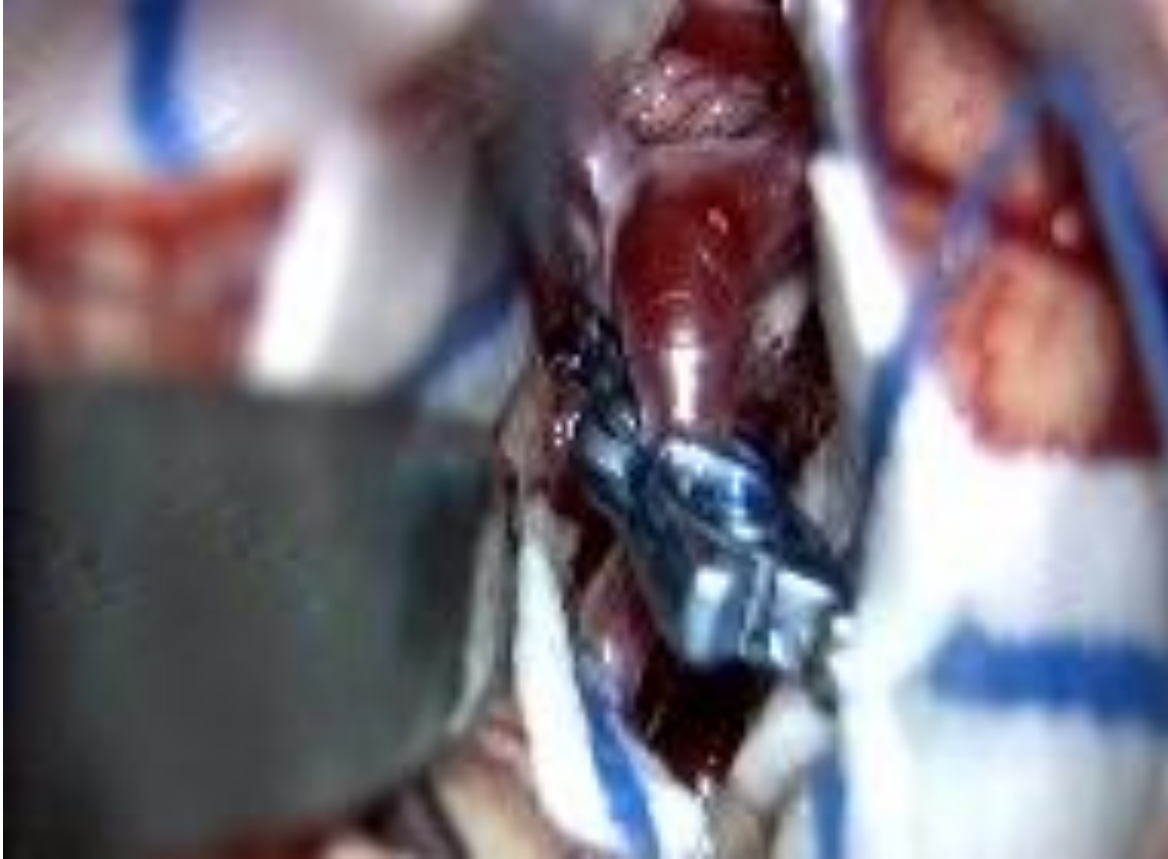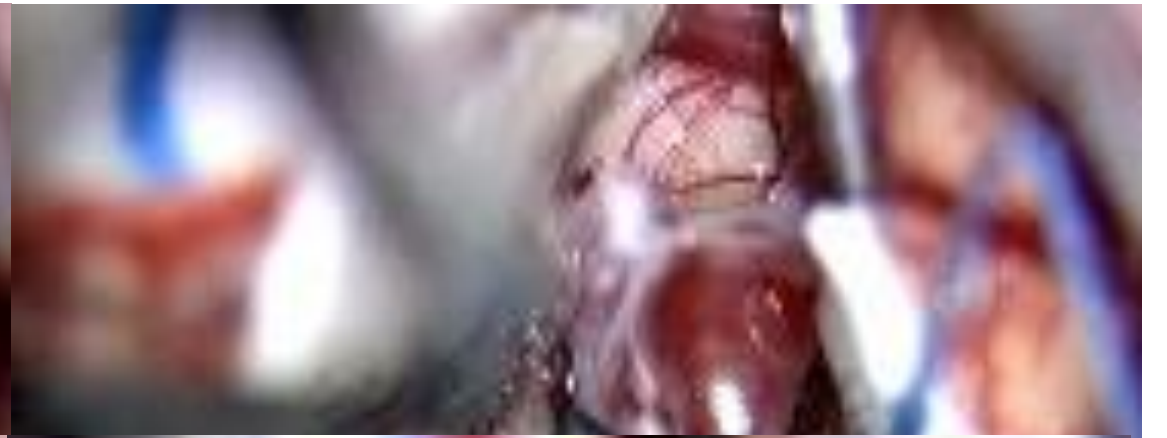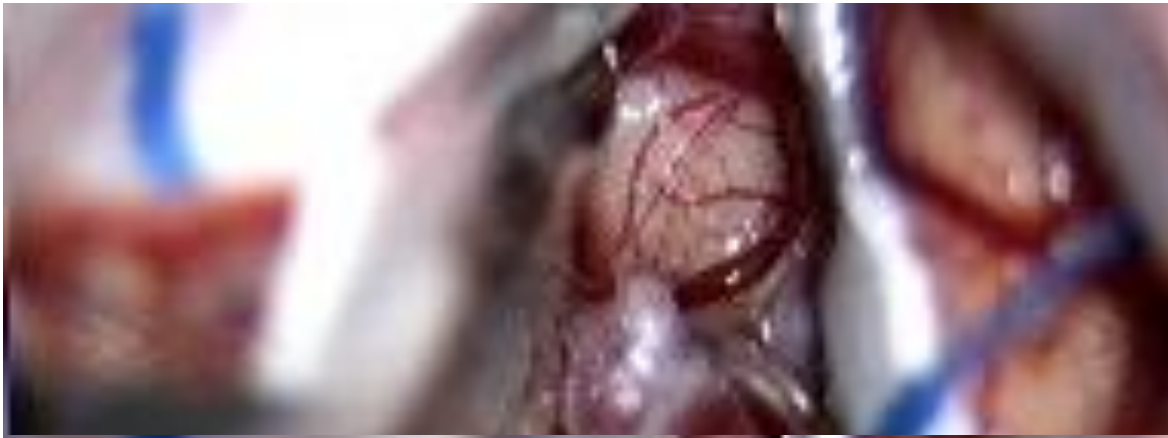- **Absolute cerebral rSO₂ <50% or a 20% decline from baseline** is associated with a higher likelihood of *cognitive decline, frontal lobe injury*, increased incidence of *stroke*, electroencephalographic silence, prolonged mechanical ventilation, and prolonged hospitalization.
- Cerebral StO₂ values less than **40%** for 10 mins, a change in baseline of more than **20%**, or a nadir of below **35%**, are associated with hypoxic-ischemic neural injury.
- Patients undergoing CABG who had *interventions* that successfully treated the identified abnormalities had significantly fewer neurologic complications and shorter hospitalizations.
- ***Overshoot phenomenon***
- Represents only *regional* cerebral perfusion; i.e., the area under the NIRS probe.

Symptomatic Hyperemia after Clipping of Unruptured Aneurysm

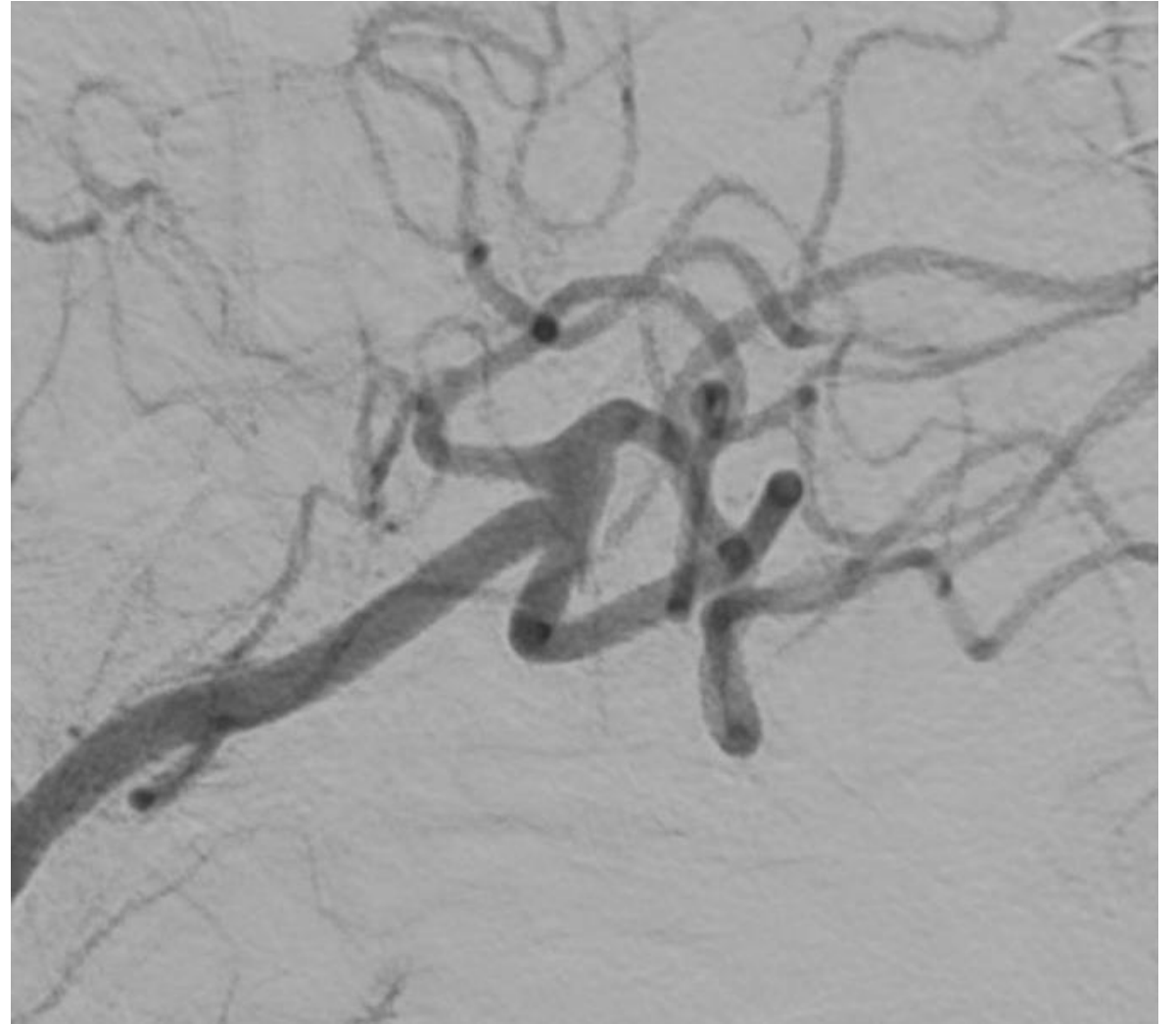
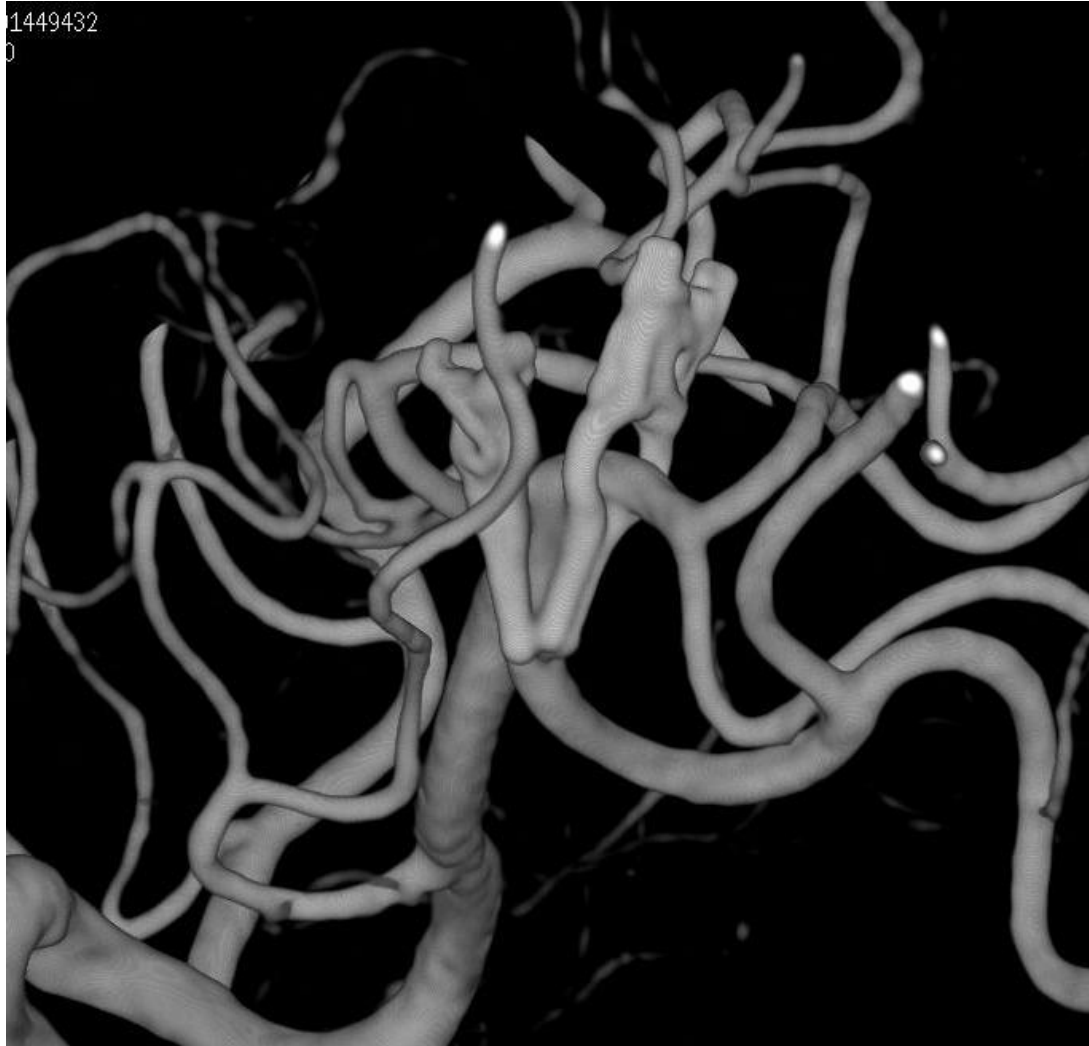Courtesy of Prof. Cho WS

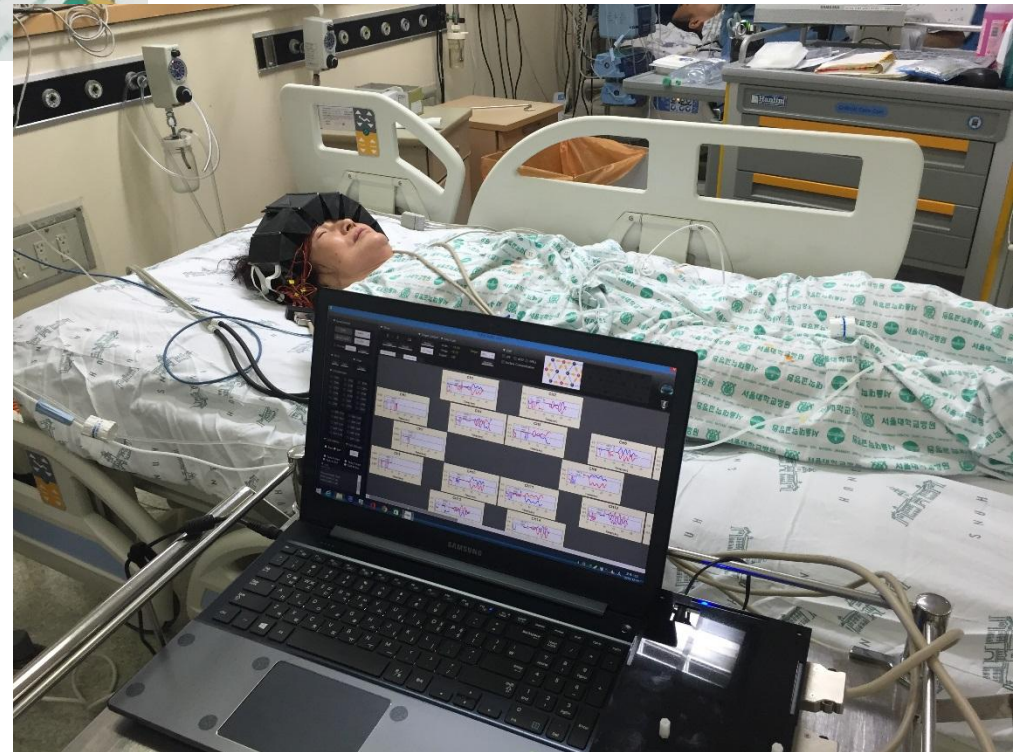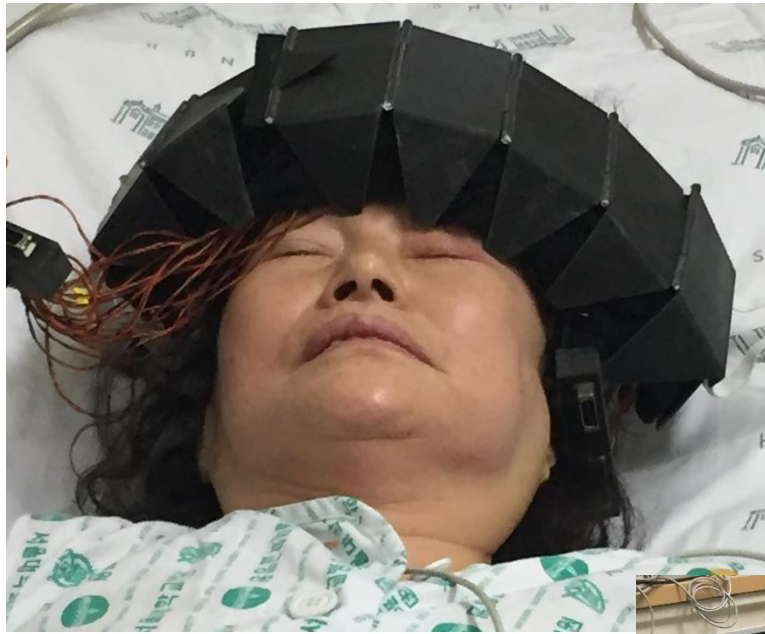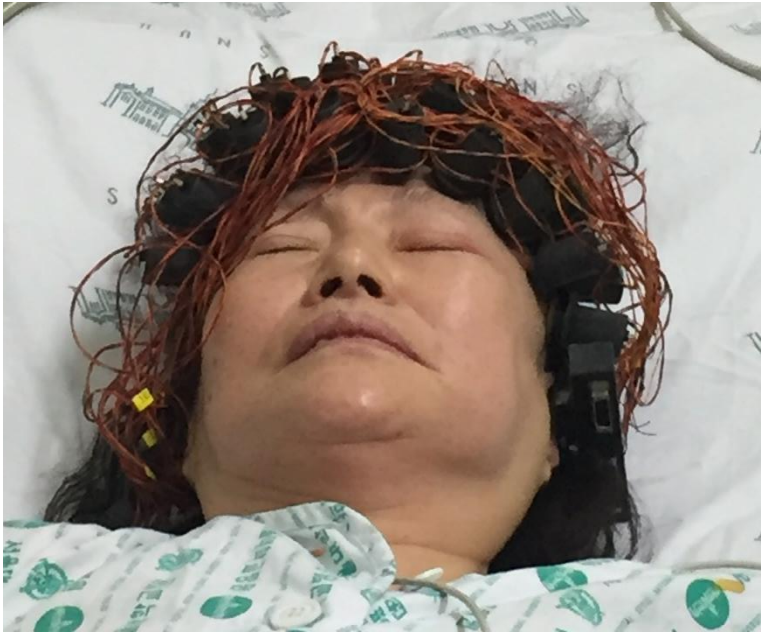68/F Multiple An. including Lt MCA An.

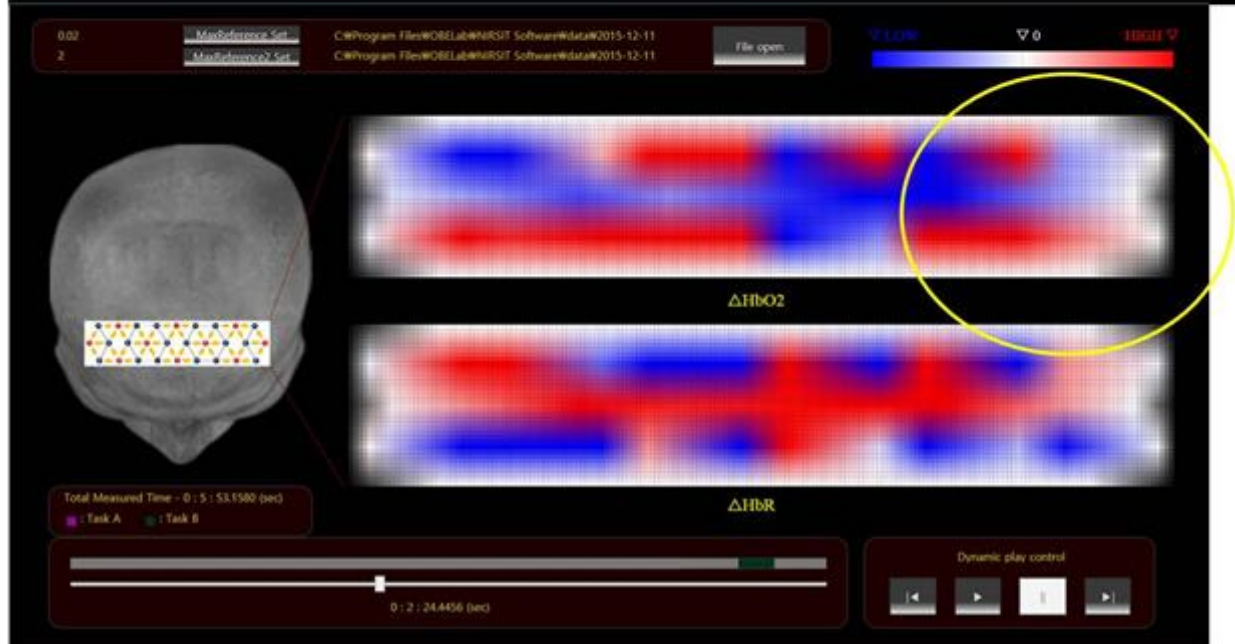
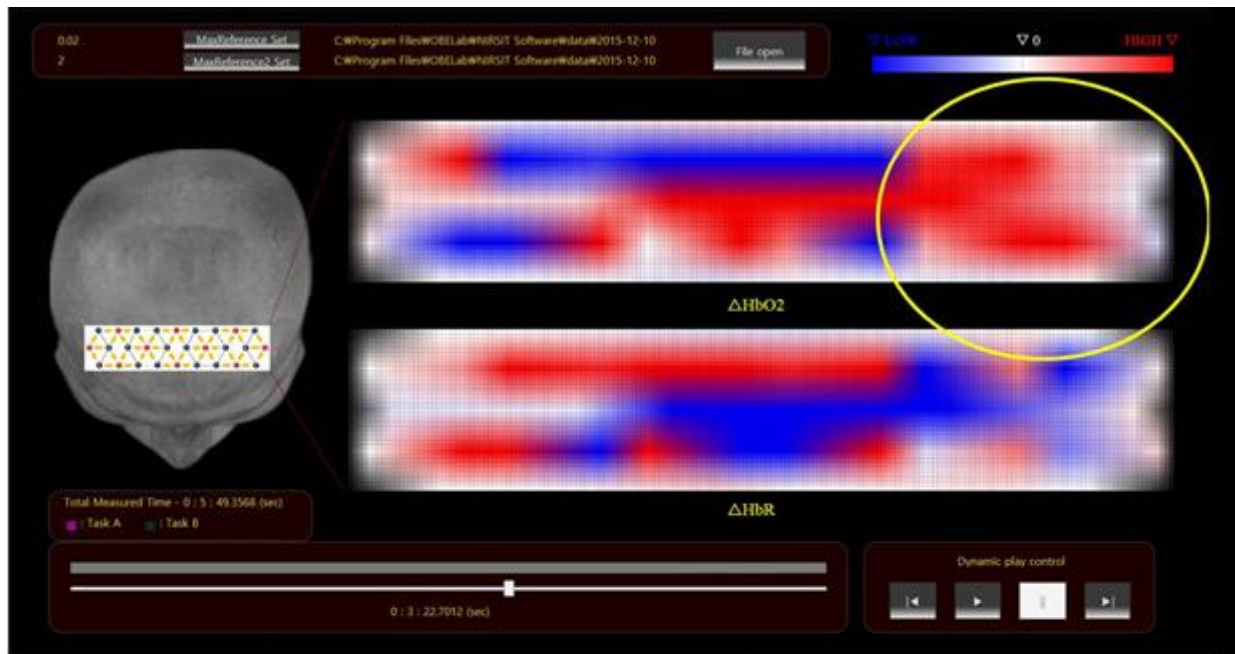




- ***Postoperative sensory dysphasia***, no abn. in DWI, TCD, and DSA







Conclusion

- Further research is needed in regard to newly emerging modalities for cerebral perfusion.
 - Arterial spin labeling MR perfusion
 - Near-infrared spectroscopy